

FLUOROSIS: A RARE CAUSE OF SPINAL CORD COMPRESSION

Maimoona Siddiqui, Azra Zafar, M. Salman and Yaseen Pathan

Department of Neurology, Liaquat National Hospital, Karachi, Pakistan

Correspondence to: Dr. Siddiqui, Consultant Neurologist, Liaquat National Hospital, Stadium Road, Karachi 74800, Pakistan. Email: drmsid@gmail.com

Pak J Neurol Sci 2007; 2(4): 217-19

ABSTRACT

Spinal cord compression due to ossification of the posterior longitudinal ligament secondary to fluorosis is very rare. There are only a handful of reports, mainly from endemic areas where fluorosis has been implicated as a cause of myelopathy, and none from Pakistan. Neurological sequelae in skeletal fluorosis arise principally because of the mechanical compression of the spinal cord and nerve roots brought about by osteophytosis and sclerosis of the vertebral column. We report a case of progressive myelopathy secondary to probable fluorosis, with remarkable imaging features.

Excessive ingestion of fluoride through water, food or dust causes acute debilitating toxicity called fluorosis.¹ Acute fluoride intoxication is rarely seen and results most frequently from accidental ingestion of large amounts of fluoride compounds. Chronic fluoride poisoning is more common and can affect animals as well as humans.²

CASE REPORT

We report the case of a 35-year-old woman, resident of Sibbi (Balochistan), with no known co-morbidities, who presented with complaints of pain in the neck, backache and progressive weakness of upper and lower limbs for two years. The weakness had increased in severity to the

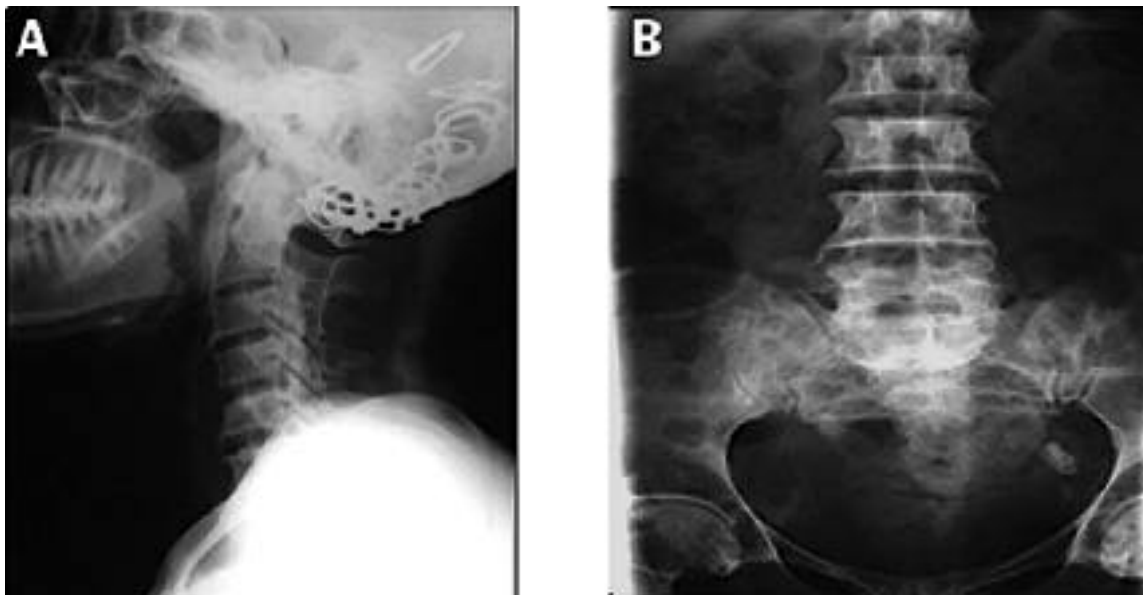


Figure 1. Plain x-rays of the cervical and lumbosacral spines. (A) Cervical spine lateral view. New bone is seen inferiorly at the level of C1-2 and posteriorly in the canal in the line of the posterior longitudinal ligament. (B) Lumbosacral spine antero-posterior view showing ossification of the sacrospinous ligament.

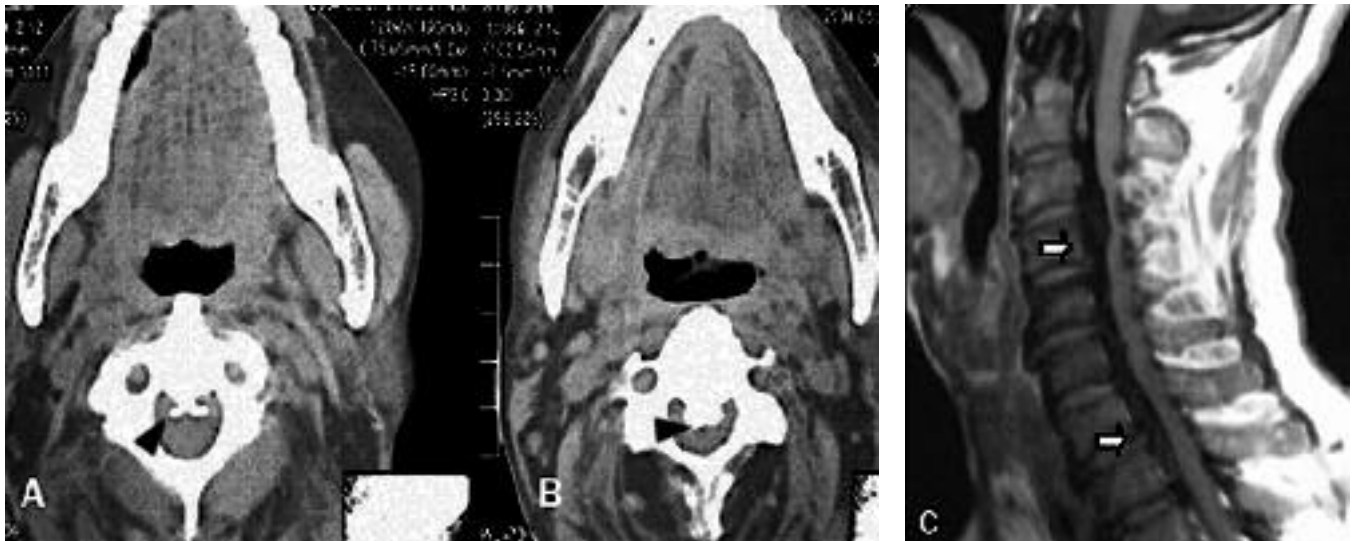


Figure 2. Ossified ligaments of the cervical spine in fluorosis. A and B: Axial computed tomography shows ossification of the posterior longitudinal ligament causing narrowing of the spinal canal (black arrowheads). C: T1-weighted demonstrates spinal cord compression (white arrows).

point that she was unable to sit or stand without support. She also complained of numbness in lower limbs but there was no associated bladder or bowel dysfunction.

On examination, she was conscious and had intact higher mental functions. Vision was decreased to only light perception; cranial nerves were otherwise intact. On motor examination, there was no atrophy or fasciculation, tone was normal, and strength was 3/5 in both upper limbs and 2/5 in the lower limbs. Deep-tendon reflexes were brisk in both upper and lower limbs with bilateral up-going plantar responses. Superficial abdominal reflexes were absent and sensory level was noted at C4. The clinical impression was of cervical myelopathy.

Standard laboratory tests, including complete blood count, erythrocyte sedimentation rate, electrolytes, calcium, albumin, and alkaline phosphatase were within normal limits. Plain x-rays of the lumbosacral spine showed ossification of the sacrospinous ligament, while x-rays of the cervical spine showed formation of new bone at the level of C1-2 and posteriorly in the canal along the line of the posterior longitudinal ligament. CT scan of the cervical spine confirmed ossification of the posterior longitudinal ligament causing narrowing of the spinal canal, with MRI of the cervical spinal also displaying cord compression (Figures 1 & 2).

DISCUSSION

Skeletal fluorosis is a bone disease caused by excessive consumption of fluoride. The United Nations Children's

Fund (UNICEF) estimates that "fluorosis is endemic in at least 25 countries across the globe," being most severe and widespread in India and China.³ Common causes include inhalation of fluoride dusts or fumes by industry workers, use of coal as an indoor fuel source, and consumption of fluoride from drinking water. Characteristic changes of fluorotic spine include ossification of the posterior longitudinal ligament and hardened bone, making the spine a continuous column of bone.⁴

Neurological involvement in fluorosis occurs in the advanced stage of the disease and is due to compression of the spinal cord and nerve roots, separately or in combination. These features usually develop after exposure to high fluoride (greater than 4 parts per million) for longer than 10 years.⁵

Spinal cord involvement is commonest in the cervical region and in one study has been reported to constitute 56% of 136 patients of fluorosis and neurological complications.⁶ Neurological symptoms are a late occurrence and signify far advanced disease. Radicular features include muscle weakness with asymmetric atrophy, fasciculation, nerve root pain and acral paresthesias. Myelopathic features are characterized by more abrupt onset and include spastic paraplegia or quadriplegia, hyperreflexia, positive Babinski sign, clonus, and a variety of sensory deficits.

The course is usually progressive. The largest numbers of cases with neurological manifestations are reported from India, with only a few case reports from other parts of the world and, to the best of our knowledge, none from

Pakistan. Interest in fluorosis has recently grown in Pakistan, with reports of skeletal and dental fluorosis, although no case so far of neurofluorosis.

Pakistan is considered a low fluoride country where 84% of all drinking water sources have suboptimal (0.7 ppm) levels of fluoride.⁷ The available data are conflicting as there are studies conducted showing increased prevalence of dental and skeletal fluorosis from Karachi, Punjab, and the Northwest Frontier Province.⁸⁻¹⁰ Fluoride levels in the drinking water of Sibbi (Balochistan province), where our patient lives, are optimal to high.⁷ In addition, coal is used as a major fuel source in that area. With characteristic radiological features showing ossification of the posterior longitudinal ligament and osteosclerosis of bones, we believe fluorosis is the cause of myelopathy in this patient.

CONCLUSION

Fluorosis should be considered in the differential diagnosis of ossification of the posterior longitudinal ligament (OPLL), especially in patients from endemic areas. MR imaging in such cases is characteristic. There is also a need to search for a cost-effective method of defluoridation of water.

REFERENCES

1. Reddy DR, et al. Neuroradiology of skeletal fluorosis. *Ann Acad Med Singapore*. 1993 May; **22**(3 suppl):493-500.
2. Reddy DR, Deme RS. Skeletal fluorosis. *Indian J Surg* 1974; **36**:30-32.
3. Skeletal fluorosis in India and its relevance to the West. Fluoride Action Network. May 2004.
4. Prasad VS, Reddy DR. Posttraumatic pseudomeningocele of cervical spine in a patient with skeletal fluorosis. Case report. *Paraplegia* 1994; **32**:627-30.
5. Haimanot RT. Neurological complications of endemic skeletal fluorosis, with special emphasis on radiculo-myelopathy. *Paraplegia* 1990 May; **28**(4):244-51.
6. Misra UK, et al. Endemic fluorosis presenting as cervical cord compression. *Arch Environmental Health* 1988; **43**:18-21.
7. Khan AA. Fluoride levels in drinking water of Pakistan. *Pakistan J Med Res* 2000; **39**:52-59.
8. Ali M. Prevalence of dental fluorosis in Karachi. *Ann Abbasi Shaheed Hosp Karachi Med Dental Coll* 2004 June; **9**(1):476-80.
9. Khan FH, Khan H. Fluorosis in Kheski area, district Nowshera. *Pak Oral Dental J* 2004 Dec; **24**(2):213-8.
10. Shabbir A, Qureshi AA, Rehman M, et al. Fluorosis in a suburb of Lahore (A report). *Pakistan J Pathol* 2001 Sept; **12**(3):139-43.