

CIRSOID ANEURYSM WITH IMPENDING RUPTURE

Amit Agrawal

Department of Neurosurgery, B.P Koirala Institute of Health Sciences, Nepal

*Correspondence to: Dr. Amit Agrawal, Assistant Professor in Neurosurgery, Department of Surgery, B.P. Koirala Institute of Health Sciences, Dharan, Nepal Tel: 977-25-525555
Ext 2047 Fax: 977-25-520251. Email: dramitagrawal@gmail.com*

Pak J Neurol Sci 2009; 4(2): 74-76

ABSTRACT

Cirroid aneurysms of the scalp are rare lesions with a propensity to massive hemorrhage. The superficial temporal artery is frequently involved in traumatic cirroid aneurysm due to its long unprotected course. Present case patient presented with frequent episodes of profuse bleeding from the lesion in last three months and developed one more episode during hospital stay. Angiography is the gold standard investigation to delineate the lesion and to exclude an intracranial component. However this facility is not available at our centre and patient could not afford to travel due to financial constraints. The lesion was delineated well with color doppler and total excision was performed by the technique described in the literature with good outcome.

INTRODUCTION

Cirroid aneurysms (arteriovenous fistulas) of the scalp are rare lesions.¹ These lesions can present as an innocuous looking subcutaneous scalp lump or a large, grotesque, pulsatile mass with a propensity to massive hemorrhage.^{2,3} The superficial temporal artery is frequently involved in traumatic cirroid aneurysm due to its long unprotected course.⁴ We discuss a case of cirroid aneurysm managed with limited resources due to financial constraints.

CASE REPORT

This 25 year lady presented with progressively increasing pulsatile swelling over right frontal region. She had three episodes of profuse bleeding from the swelling in last three months. She sustained blunt trauma to the right forehead in her childhood. Her general and systemic examination was unremarkable. There were no focal neurological deficits. Local examination revealed 8 x 8 cm soft, compressible, pulsatile swelling with prominent, dilated and tortuous vessels. Skin over it was healthy except unhealthy scab in the centre. No bony defect was palpable. There was prominent, tortuous and pulsatile

right superficial temporal artery with dilated frontal veins. Ultrasound color doppler showed dilated tortuous vessels in the right fronto-temporal region with arterialization of the veins. There was increased blood flow in the right superficial temporal artery. There was also evidence of increased blood flow in the diploic veins suggestive of local trans-cranial drainage (Figure 1). All these findings were suggestive of cirroid aneurysm fed by right superficial temporal artery. At our institution there are no facilities for angiogram and patient was not affordable to go to any other place. Patient also developed sudden bleeding from the lesion. She was planned for emergency surgical excision of the lesion. Bicornal scalp flap was planned based on the principles described (to avoid flap necrosis and for adequate exposure) in the literature and the feeding anterior branch of right superficial artery was cut between ligatures.^{2,5} The scalp flap was raised along with the pericranium. The bleeding from the bone is controlled with bone wax and monopolar diathermy. Other feeding arteries were identified along their course at the base of the scalp flap, and the vessels traced distally towards the nidus of the scalp malformations and ligated. The pericranium and the galea are circumferentially incised and the vascular malformation was excised.^{2,5} On follow up patient was doing well and color Doppler showed total excision of the lesion (Figure 1).

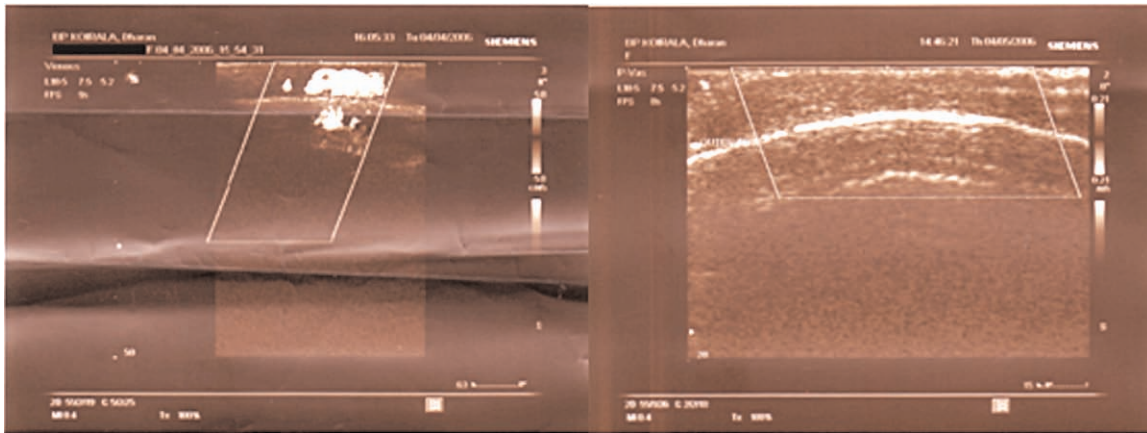


Figure 1: Color doppler of the scalp showing vascular malformation and increased flow in the diploic bone (left), post-operative color Doppler (right) showing complete excision of the lesion

DISCUSSION

The etiology of cirroid aneurysms is still controversial. However, it is generally accepted that it may be either of congenital or traumatic origin.² About 10 to 20% of scalp arteriovenous malformations develop following penetrating or non-penetrating trauma to the scalp.^{6,7} Most of the patients reported in the literature had a history of progressive increase in the size of the lesion and had become symptomatic in the third decade of life.¹ The clinical manifestations relate primarily to the size of the fistula, and patients may present with loud bruit, hemorrhage, and throbbing headache and in severe cases, scalp necrosis.⁴ Hemorrhage from these lesions is uncommon and usually associated with large vascular malformation.⁵ Angiography is the gold standard investigation to delineate the lesion and to exclude an intracranial component.⁸ Other supplementary investigations are CT, MRI, MRA, angiography and color doppler studies.¹ In treating these types of AVM, surgical excision has been the most common method of obliteration. These procedures are necessarily extensive, and, for a complete cure, the entire fistula had to be removed; otherwise, an AVM will likely recur, together with recruitment of a collateral blood supply.^{1,9,10} Other treatment modalities in cases of a cirroid aneurysm or AVM of the scalp or face, direct-puncture embolization with NBCA, absolute alcohol, or a metallic thrombogenic coil with good results has been reported.^{11,12}

CONCLUSION

Diagnosis of cirroid aneurysm of the scalp can be made easily on clinical grounds and a complete angiographic study of the lesion is the gold standard. However when the

facilities and affordability are limiting factors and patient needs emergency care as in the present case optimum use of available resources, supported by the literature can result in good outcome.

REFERENCES

1. Muthukumar N, Rajagopal V, Manoharan AV, Durairaj N. Surgical management of cirroid aneurysms. *Acta Neurochir (Wien)*. 2002;**144(4)**:349-56.
2. Domingo Z, Fisher-Jeffes ND, deVilliers JC. Surgical management of arteriovenous malformations of the scalp. In Schmidek HN, editor. *Operative neurosurgical techniques: Indications, methods and results*. 4th Ed. Philadelphia: Saunders Company; 2000. p. 1331-8.
3. Weinzweig N, Chin G, Polley J, Chabrel F, Shownkeen H, Debrun G. Arteriovenous malformation of the forehead, anterior scalp and nasal dorsum. *Plast Reconstr Surg* 2000;**105**:2433-9.
4. Barnwell SL, Halbach VV, Dowd CF, Higashida RT, Hieshima GB. Endovascular treatment of scalp arteriovenous fistulas associated with a large varix. *Radiology* 1989;**173**:533-9.
5. Shenoy SN, Raja A. Scalp arteriovenous malformations. *Neurology India* 2004; **52(4)**: 478-481.
6. Morioka T, Nishio T, Hikita T. Traumatic arteriovenous fistulae of the scalp at the area of the previous craniotomy. *Surg Neurol* 1988; **30**:404-7.
7. Badejo L, Rockwood P. Traumatic arteriovenous fistula of the scalp. Case report. *J Neurosurg* 1987;**66**:773-4.

8. Wilkinson HA. Recurrence of vascular malformation of the scalp 18 years following excision. Case report. *J Neurosurg* 1971;**34**:435-7.
9. Merland JJ. Discussion on hemodynamic considerations in the treatment of arteriovenous malformations of the face and scalp. *Plast Reconstr Surg* 1981;**67**:433- 434.
10. Erdmann MWH, Davies DM, Jackson JE, Allison DJ. Multidisciplinary approach to the management of head and neck arterio-venous malformations. *Ann R Coll Surg Engl* 1995; **77**:53-59.
11. Han MH, Seong SO, Kim HD, Chang K, Yeon KM, Han MC. Craniofacial Arteriovenous Malformation: Preoperative Embolization with Direct Puncture and Injection of n-Butyl Cyanoacrylate. *Radiology* 1999; **211**:661-666
12. Heilman CB, Kwan ES, Klucznik RP, Co'hen AR. Elimination of cirroid aneurysm of the scalp by direct percutaneous embolization with thrombogenic coils. *J Neurosurg* 1990;**73**:296-300.