

OVERVIEW OF SURGICAL MANAGEMENT OF INFECTIOUS NON-SUPPURATIVE BRAIN LESIONS (PART I)

Muhammad Shahzad Shamim,¹ Syed Ather Enam,¹ Rushna Pervez Ali,¹ Syed Faizan Ali¹ and Mohammad Wasay²

¹ Department of Neurosurgery, Aga Khan University, Karachi, Pakistan

² Department of Neurology, Aga Khan University, Karachi, Pakistan

Correspondence to: Dr. Enam, Associate Professor and Head of Neurosurgery, Departments of Surgery and Biological & Biomedical Sciences, Aga Khan University Hospital, P.O. Box 3500 Stadium Road, Karachi 74800 Pakistan. e-mail: ather.enam@aku.edu, Tel no: 00 92 (21) 486-4710, 4764

Pak J Neurol Sci 2009; 4(2):77-82

INTRODUCTION

Infectious brain lesions include all space occupying lesions within the cranium, secondary to an infective etiology. They account for a small proportion of all intracranial space occupying lesions and are a result of infections due to various organisms. The most common organism recovered from cultures is the bacterium *Streptococcus*. However, a wide variety of other bacteria (*Proteus*, *Pseudomonas*, *Pneumococcus*, *Meningococcus*, *Haemophilus*), fungi and parasites may also cause the disease. Fungi and parasites are especially associated with immunocompromised patients. Toxoplasmosis and neurocysticercosis are the commonest parasitic infections of the CNS, with *Entamoeba histolytica*, *Naegleria* and *Acanthamoeba* also making a small contribution. *Candida*, *Aspergillus* and *Cryptococcus neoformans* are commonest among fungi, whereas *Herpes Simplex virus* and *Cytomegalovirus* are the leading cause of viral abscesses. We classify these lesions in to two broad categories; namely suppurative space occupying lesions such as brain abscesses, and non-suppurative space occupying lesions such as tuberculomas and hydatid cysts (Table 1). Brain abscesses of any etiology are neurosurgical emergencies and require urgent and aggressive management. Tuberculoma, hydatid cysts and similar non-suppurative lesions on the other hand behave like brain tumors, which can usually be investigated and the management can be planned non-urgently. The morbidity and mortality of the two pathologies is likewise different, and where suppurative lesions follow a rapid natural course with mostly poor outcome, non-suppurative lesions usually carry a much slower course with fairly acceptable outcomes.

In this review, the authors shall be discussing the three more common forms of infectious non-suppurative brain lesions namely tuberculomas, aspergillomas and hydatid cysts which, although categorized under the same class,

Table 1. Proposed Classification of Infectious Brain Lesions

Suppurative	Non suppurative
Bacterial Acute: <i>Streptococcus</i> species <i>Staphylococcus aureus</i> <i>Hemophilus influenzae</i> <i>Bacteroides fragilis</i> Chronic: <i>Mycobacterium tuberculosis</i>	Bacterial Healed suppurative lesions <i>Mycobacterium tuberculosis</i> (Neurotuberculoma)
Fungal or fungus like bacteria <i>Aspergillus fumigatus</i> <i>Candida albicans</i> <i>Histoplasma capsulatum</i> <i>Cryptococcus neoformans</i> <i>Nocardia asteroides</i>	Fungal <i>Aspergillus fumigatus</i> (Neuroaspergilloma) <i>Cryptococcus mucinosis</i> Pseudocysts (Neurocryptococcoma)
Protozoal <i>Entamoeba histolytica</i> <i>Toxoplasma gondii</i>	Helminthic <i>Echinococcus granulosus</i> (Neurohydatidosis) <i>Taenia solium</i> (Neurocysticercosis)
Acute suppurative infection of non suppurative lesions	Viral <i>Herpes Simplex Virus</i> <i>Cytomegalovirus</i>

behave very differently and thus require unique and specific management strategies. This part I of the article focuses on tuberculomas; aspergillomas and hydatid cysts will be discussed in the subsequent parts.

TUBERCULOMAS

Intracranial tuberculomas are frequently seen in endemic

areas.¹ In these areas tuberculomas account for 5-30 % of all intracranial space occupying lesions and due to the high prevalence of the disease most patients are commenced on empirical anti-tuberculous therapy based on suggestive clinical and radiological features alone.^{2,3} Such an approach has been previously advocated and in the presence of a known primary tuberculous focus, seems reasonable. The incidence in non-endemic areas is also on a rise due to migration of individuals from endemic areas, as well as due to the growing population of patients who are immunocompromised and thus more susceptible to tuberculous infection. In endemic areas CNS tuberculosis is considered to follow the ten percent rule.⁴ There are an estimated 10 million new cases of tuberculosis worldwide, nearly 10 % of all patients with tuberculosis tend to have CNS involvement either as tuberculous meningitis or as intracranial tuberculomas and till date the reported literature suggested that the two conditions may co-exist in up to 10 % of patients. In endemic areas, 10 % of all intracranial space occupying lesions are tuberculomas and the mortality of intracranial tuberculomas has also been reported at around 10 %. Almost 70 % of patients have multiple tuberculomas.⁵

Mycobacterium tuberculosis is an acid fast bacillus and an obligate aerobe. The bacteria therefore primarily affect the lungs but can also cause disease in almost any other tissue of the body most commonly lymph nodes, kidneys, brain. In our experience this miliary pattern has been associated with worse outcomes.⁶ The hallmark of the disease is the formation of granulomas which are combination of macrophages, multinucleated giant cells, fibroblasts and collagen deposits surrounding granular creamy cheese like caseous necrosis which may exhibit acid fast bacilli.⁴ The organism may remain dormant for long durations but it is viable and can reactivate if the patients' immunity is suppressed. Small granulomas (incipient tubercles) later coalesce to form larger granulomas and when present in brain these are termed as intracranial tuberculomas. Since such an inflammatory response requires an intact immune response, tuberculomas are more commonly seen in immune-competent patients. The unaffected brain parenchyma around these tuberculomas may show edema and astrocytic proliferation.⁷

Tuberculomas grow slowly and displace normal brain tissue rather than destroy it. Very large tuberculomas have been referred to by few authors as giant tuberculomas.^{8,9} Based on our own experience and recent reports which suggest poor response of tuberculomas larger than 4 centimeters even on prolonged periods of anti-tuberculous therapy, we propose that tuberculomas larger than 4 centimeters in their greatest dimension be considered giant tuberculomas.

Table 2. AKUH Management Guidelines for Intracranial Tuberculomas

Location	Size 0-1 cm	Size 1-4 cm	Size >4cm (Giant)
Eloquent	ATT	ATT	Partial excision + ATT
Non-Eloquent	ATT	ATT +/- excision	Total excision + ATT

There appear to be no gender or age related predilections of the disease and the mean age has been reported to be 30 years, however, they are uncommon at extremes of age. Children present more commonly with tuberculous meningitis or arachnoiditis and hydrocephalus rather than tuberculomas.¹⁰ At our centre, only about 30 % of patients with tuberculomas actually have a prior history or a history of contact with tuberculosis.⁶ Less than 20 % patients with tuberculomas at our centre were found to be immunocompromised, of which 7 % were considered immunocompromised on the basis of pregnancy or puerperium.⁶ Presentation is either due to mass effect, associated meningitis, or seizures.^{6,11} A history of fever and weight loss is strongly suggestive of an intracranial tuberculoma, if the radiological features support the diagnosis.¹² The most common presenting features in our published series of more than one hundred patients with tuberculomas was fever and headaches while the commonest signs were drowsiness and cranial nerve palsies, especially facial and abducent nerves.^{13,14} More than 70 % of patients in our series had multiple tuberculomas at presentation and more than 30 % of patients had both supratentorial and infratentorial tuberculomas, hence the clinical picture can vary greatly.⁶ This is in contrast to previous reports which suggest that solitary tuberculoma is more common.⁶ The mean number of lesions in our series (4.5 lesions per patient) was also higher than in previous reports, which could be due to the preserved immune status in majority of our patients, as it has been reported that immunocompromised patients may have fewer tuberculomas perhaps due to a deficient immune response necessary for formation of tuberculomas.^{6,15} Very rarely patients presenting with signs of raised intracranial pressure may be found to have more than a hundred lesions on imaging, a condition that has been introduced as tuberculomatosis cerebri.^{5,6}

Laboratory work up may be inconclusive in patients with intracranial tuberculomas but in the presence of other parameters may help to reach the diagnosis. Anemia and peripheral leukocytosis may be seen in up to half of these patients, more commonly in those with associated systemic tuberculosis and tuberculous abscesses.⁶ Elevated erythrocyte sedimentation rate (ESR) in patients with a suggestive history is considered more specific as it is seen in more than 60% of patients.⁶ We do not

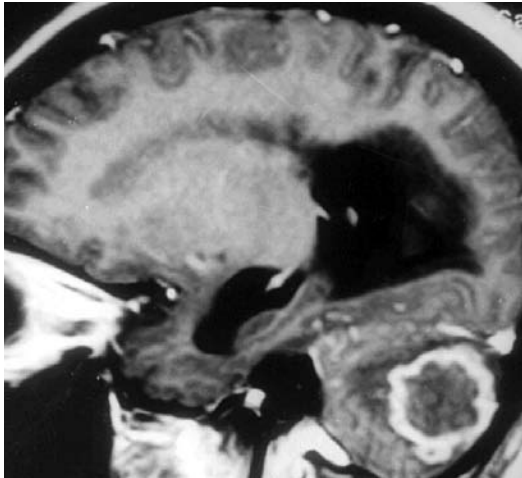


Figure 1: Post contrast MRI in sagittal plane showing a large tuberculoma in cerebellum with edema and hydrocephalus

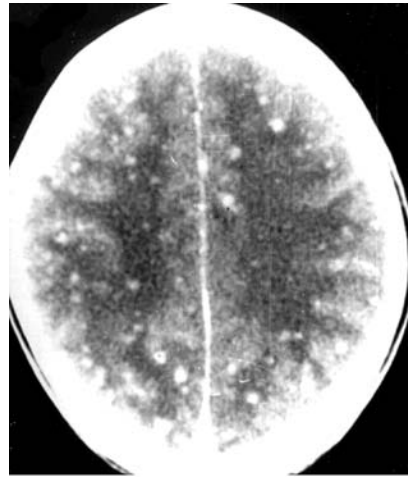


Figure 2: Post contrast brain CT scan in axial plane showing multiple enhancing lesions throughout brain, histologically proven to be tuberculomas

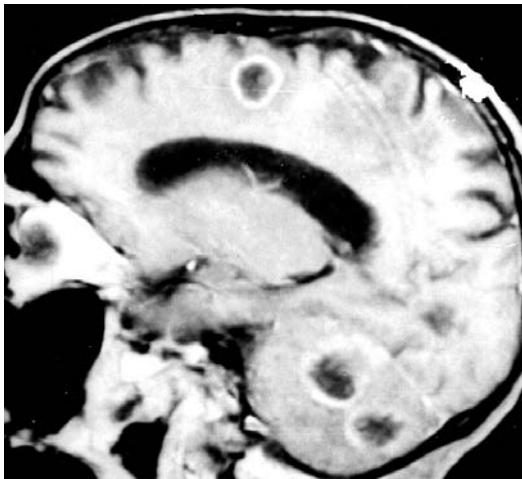


Figure 3: Post contrast MRI in sagittal plane showing multiple tubercular lesions in frontal lobe, occipital lobe and cerebellum

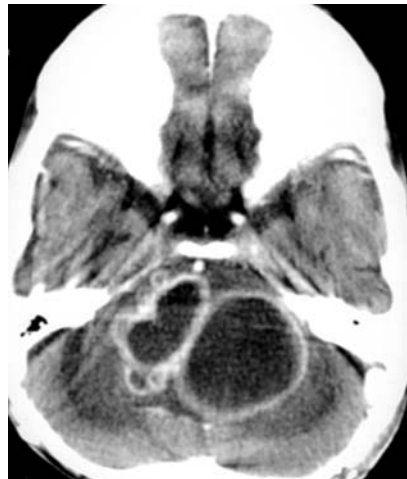

Figure 4: Post contrast CT scan in axial plane showing multilobular tuberculoma involving pons and cerebellum

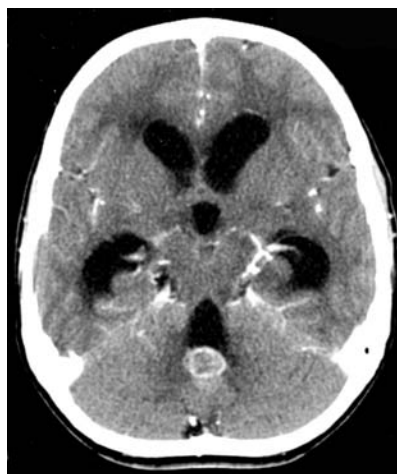

Figure 5: Post contrast CT scan in axial plane showing a tuberculoma adjacent to fourth ventricle with hydrocephalus

recommend lumbar puncture in these patients but cerebrospinal fluid (CSF) analysis may show characteristic picture of elevated protein counts, elevated cell counts (classically lymphocytes) and low CSF glucose levels.¹⁶ Acid fast bacteria may be noticed on staining but CSF cultures are hardly ever positive and take six weeks for finalization. CSF polymerase chain reaction (PCR) is quicker, more sensitive as well as specific and should be carried out routinely in endemic areas, although availability and cost are two limitations of the test.¹⁷ Tissue cultures on the other hand are even more sensitive than PCR.¹⁸ Whenever tissue can be acquired safely for confirmation of diagnosis, it should be preferred.¹⁹ Histopathology, however, remains the gold standard.²⁰

The CT appearance of tuberculoma is diverse and the famous target sign and calcification, previously associated with tuberculomas has been rarely seen at our centre.^{5,21,22} The lesion may be hyperdense due to a high protein or calcium content, or hypodense due to necrosis. Enhancement pattern may also be nonspecific with most lesions showing homogenous or ring enhancement.² Magnetic resonance appearance of tuberculoma is diverse and relates to the histological stage of tuberculoma.²³ Small lesions most commonly appear isointense on T1 weighted images and hyperintense on T2 weighted and FLAIR images, and less commonly hypointense on T2 weighted images. As for the larger lesions, non contrast T1 weighted images may show iso or hypointense lesion with or without hypointense surrounding rim and non contrast T2 weighted images may show a variety of combinations such as a hypointense core with hyperintense rim, hyperintense core without rim, hyperintense core with hypointense rim.⁵ The pattern of enhancement is usually the same as in CT scans i.e. it may show homogenous, ring like, or less commonly, lobular patterns. FLAIR images are relatively more sensitive and show isointense or hypointense core with hyperintense rim and surrounding edema. Core hypointensity has been shown to correlate with necrosis and hypercellularity. Caseous necrosis is specific for tuberculosis and is characterized by relatively large amount of lipid contents within the tuberculomas.⁵ MRI scans are more sensitive for diagnosing accurate number of lesions, perilesional edema and meningeal enhancement.²⁴ Differential diagnosis include metastases, high grade gliomas, neurocysticercosis, among other enhancing lesions.^{15,25} (Figure 1-5)

No other CNS infection has seen such a change in management principles as tuberculosis.^{11,26,27} Initial literature is filled with reports of successful treatments with surgical excision of tuberculomas up to mid 1980s, but with the introduction of better medications and with reports of equal or even better results with anti tuberculous therapy alone, the paradigm shifted towards

non-surgical management.²⁸ Patients in endemic areas were managed on the basis of clinical suspicion alone without the need for histological diagnosis. Neurosurgical intervention was restricted to stereotactic or CT guided biopsies of suspect lesions or lesions not responding to medications.²⁰ Recent reports however suggest that medical therapy may be insufficient for complete cure of these lesions, with 20-46% of the lesions failing to resolve on prolonged (18 months) of anti-tuberculous therapy alone.^{11,18}

It has been recommended that medical management be initiated for most tuberculomas which can be diagnosed with reasonable confidence based only on their clinical and radiological features.^{29,30} Whenever the diagnosis is suspect, the choice is between an empirical course of anti tuberculous therapy followed by repeat imaging or a biopsy of the most superficial lesion in the least eloquent area is recommended.^{2,3} For biopsy, excision of the entire tuberculoma is always preferable if it can be done safely.³ If lesions near eloquent areas need to be biopsied, stereotactic neuronavigation or ultrasound guided aspirations are useful. For giant tuberculomas, or tuberculomas not responding to therapy, or tuberculomas causing significant mass effect, surgical excision should be considered. When more than one lesion is present, giant tuberculomas are excised.¹⁸ An aggressive attitude towards these giant tuberculomas is based on our experience that these hardly ever resolve with medical therapy alone, require long duration of therapy, have a high risk of reactivation and may show the paradoxical effect. Debulking of these lesions not only reduces bulk but also improves antibiotic penetration and lowers steroid requirements.¹⁸ Partial excision of tuberculomas carries a higher risk of post-operative hemorrhage. The post-operative course is usually unremarkable. We as a policy recommend biopsy for all suspected intracranial tuberculomas prior to initiation of chemotherapy.

The standard treatment regimen is based on four drugs which include isoniazid, rifampicin, pyrazinamide and ethambutol or streptomycin. Isoniazid and pyrazinamide have relatively better CSF penetration and this regimen is equally effective for concomitant tuberculous meningitis.³¹ There is no consensus on the rate of resolution of intracranial tuberculomas and consequently on optimal duration of therapy.^{11,18,28,32} Recommended duration of antituberculous therapy is at least 9 to 18 months, depending upon the patient's clinical and radiological response, but may have to be continued for longer or changed to second line medications.^{11,27,33,34} Sometimes despite adequate antimicrobial coverage, the tuberculoma may increase in size, a phenomena referred to as the paradoxical response. This generally occurs over a period of 1 to 3 months after the commencement of chemotherapy.^{35,36} We suggest that under such

circumstances, serious thought should be given to re-confirmation of diagnosis and/or excision of tuberculomas. Use of corticosteroids is reserved only for selected patients who have significant mass effect due to perilesional edema.

Sequelae of disease include re-activation tuberculosis, drug resistance, hydrocephalus, seizures and paradoxical response to anti tuberculous therapy.²⁸ Serial brain imaging is essential to determine the length of therapy. Intracranial tuberculomas usually carry a favorable prognosis and the predictors of poor outcome include coma at presentation and evidence of miliary tuberculosis.⁶ Majority of patients make complete recovery although some may have deficits. In our series which is one of the largest published so far, the mortality was 11 %.⁶

This is the end of Part I which discussed Tuberculoma in detail; in Part II we will be discussing Aspergilloma, its etiology, signs and symptoms, diagnosis and management.

REFERENCES

- Nadkarni T, Goel A. Aspergilloma of the brain: an overview. *J Postgrad Med*2005;51 Suppl 1:S37-41.
- Selvapandian S, Rajshekhar V, Chandy MJ, Idikula J. Predictive value of computed tomography-based diagnosis of intracranial tuberculomas. *Neurosurgery*1994 Nov;**35(5)**:845-50; discussion 50.
- Bouchama A, al-Kawi MZ, Kanaan I, Coates R, Jallu A, Rahm B, et al. Brain biopsy in tuberculoma: the risks and benefits. *Neurosurgery*1991 Mar;**28(3)**:405-9.
- Zuger A LF. Infections of Central Nervous System. 1997 ed. WM Scheld RW, DT Durack, editor. New York: Lippincott-Raven Publishers; 1997.
- Wasay M, Kheleani BA, Moolani MK, Zaheer J, Pui M, Hasan S, et al. Brain CT and MRI findings in 100 consecutive patients with intracranial tuberculoma. *J Neuroimaging*2003 Jul;**13(3)**:240-7.
- Wasay M, Moolani MK, Zaheer J, Kheleani BA, Smego RA, Sarwari RA. Prognostic indicators in patients with intracranial tuberculoma: a review of 102 cases. *J Pak Med Assoc*2004 Feb;**54(2)**:83-7.
- Whitener DR. Tuberculous brain abscess. Report of a case and review of the literature. *Arch Neurol*1978 Mar;**35(3)**:148-55.
- Parihar V, Yadav YR, Sharma D. Giant extra-axial posterior fossa tuberculoma in a three-year-old child. *Neurol India*2009 Mar-Apr;**57(2)**:218-20.
- Khanna PC, Godinho S, Patkar DP, Pungavkar SA, Lawande MA. MR spectroscopy-aided differentiation: "giant" extra-axial tuberculoma masquerading as meningioma. *AJNR Am J Neuroradiol*2006 Aug;**27(7)**:1438-40.
- Farinha NJ, Razali KA, Holzel H, Morgan G, Novelli VM. Tuberculosis of the central nervous system in children: a 20-year survey. *J Infect*2000 Jul;**41(1)**:61-8.
- Rajeswari R, Sivasubramanian S, Balambal R, Parthasarathy R, Ranjani R, Santha T, et al. A controlled clinical trial of short-course chemotherapy for tuberculoma of the brain. *Tuber Lung Dis*1995 Aug;**76(4)**:311-7.
- Muin IA, Zurin AR. Pulmonary miliary tuberculosis with multiple intracerebral tuberculous granulomas-- report of two cases. *Br J Neurosurg*1998 Dec;**12(6)**:585-7.
- Arseni C. Two hundred and one cases of intracranial tuberculoma treated surgically. *J Neurol Neurosurg Psychiatry*1958 Nov;**21(4)**:308-11.
- Bagga A, Kalra V, Ghai OP. Intracranial tuberculoma. Evaluation and treatment. *Clin Pediatr (Phila)*1988 Oct;**27(10)**:487-90.
- Bayindir C, Mete O, Bilgic B. Retrospective study of 23 pathologically proven cases of central nervous system tuberculomas. *Clin Neurol Neurosurg*2006 Jun;**108(4)**:353-7.
- Thwaites G, Chau TT, Mai NT, Drobniowski F, McAdam K, Farrar J. Tuberculous meningitis. *J Neurol Neurosurg Psychiatry*2000 Mar;**68(3)**:289-99.
- Baker CA, Cartwright CP, Williams DN, Nelson SM, Peterson PK. Early detection of central nervous system tuberculosis with the gen-probe nucleic Acid amplification assay: utility in an inner city hospital. *Clin Infect Dis*2002 Aug 1;**35(3)**:339-42.
- Poonnoose SI, Rajshekhar V. Rate of resolution of histologically verified intracranial tuberculomas. *Neurosurgery*2003 Oct;**53(4)**:873-8; discussion 8-9.
- Schutte CM, Van der Meyden CH, Labuscagne JH, Otto D. Lymph node biopsy as an aid in the diagnosis of intracranial tuberculosis. *Tuber Lung Dis*1996 Jun;**77(3)**:285-6.
- Lee WY, Pang KY, Wong CK. Brain tuberculoma in Hong Kong. *Hong Kong Med J*2002 Feb;**8(1)**:52-6.
- Jenkins JR. Computed tomography of intracranial tuberculosis. *Neuroradiology*1991;**33(2)**:126-35.
- Ng SH, Tang LM, Lui TN, Ko SF, Wong HF, Wai YY, et al. Tuberculoma en plaque: CT. *Neuroradiology*1996 Jul;**38(5)**:453-5.
- Gupta RK, Pandey R, Khan EM, Mittal P, Gujral RB, Chhabra DK. Intracranial tuberculomas: MRI signal intensity correlation with histopathology and localised proton spectroscopy. *Magn Reson*

- Imaging*1993;**11(3)**:443-9.
24. Gupta RK, Husain N, Kathuria MK, Datta S, Rathore RK, Husain M. Magnetization transfer MR imaging correlation with histopathology in intracranial tuberculomas. *Clin Radiol*2001 Aug;**56(8)**:656-63.
 25. Batra A, Tripathi RP. Diffusion-weighted magnetic resonance imaging and magnetic resonance spectroscopy in the evaluation of focal cerebral tubercular lesions. *Acta Radiol*2004 Oct;**45(6)**:679-88.
 26. Arvind C, Korath MP, Raveendranadhan K, Jagadeesan K. A retrospective study of 1247 cases of intracranial tuberculomata diagnosed by computerized tomography. *J Assoc Physicians India*1993 Sep;**41(9)**:559-61.
 27. Bass JB, Jr., Farer LS, Hopewell PC, O'Brien R, Jacobs RF, Ruben F, et al. Treatment of tuberculosis and tuberculosis infection in adults and children. American Thoracic Society and The Centers for Disease Control and Prevention. *Am J Respir Crit Care Med*1994 May;**149(5)**:1359-74.
 28. Awada A, Daif AK, Pirani M, Khan MY, Memish Z, Al Rajeh S. Evolution of brain tuberculomas under standard antituberculous treatment. *J Neurol Sci*1998;**156(1)**:47-52.
 29. Tandon PN, Bhargava S. Effect of medical treatment on intracranial tuberculoma--a CT study. *Tubercle*1985 Jun;**66(2)**:85-97.
 30. Tandon PN. Brain biopsy in tuberculoma: the risks and benefits. *Neurosurgery*1992 Feb;**30(2)**:301.
 31. Nau R, Prange HW, Menck S, Kolenda H, Visser K, Seydel JK. Penetration of rifampicin into the cerebrospinal fluid of adults with uninflamed meninges. *J Antimicrob Chemother*1992 Jun;**29(6)**:719-24.
 32. Harder E, Al-Kawi MZ, Carney P. Intracranial tuberculoma: conservative management. *Am J Med*1983 Apr;**74(4)**:570-6.
 33. Wang S, Yang T, Jiang M. [CT scanning and treatment of intracranial tuberculoma]. *Zhonghua Jie He He Hu Xi Za Zhi*1996 Apr;**19(2)**:107-9.
 34. Gropper MR, Schulder M, Sharan AD, Cho ES. Central nervous system tuberculosis: medical management and surgical indications. *Surg Neurol*1995 Oct;**44(4)**:378-84; discussion 84-5.
 35. Afghani B, Lieberman JM. Paradoxical enlargement or development of intracranial tuberculomas during therapy: case report and review. *Clin Infect Dis*1994 Dec;**19(6)**:1092-9.
 36. Bas NS, Guzey FK, Emel E, Alatas I, Sel B. Paradoxical intracranial tuberculoma requiring surgical treatment. *Pediatr Neurosurg*2005 Jul-Aug;**41(4)**:201-5.