

# SPONTANEOUS THORACIC SPINAL EPIDURAL HEMATOMA IN THE POST-PARTUM PERIOD

**Sardar M. Alam, Haroon Khan, Rafi ud Din, Faiqa Filza, Tariq Khan.**

*Department of Neurology & Neurosurgery; Northwest General Hospital & Research Centre, Peshawar, Pakistan.*

*Correspondence to: Dr. S.M.Alam FRCP (EDIN), Consultant Neurologist, Northwest General Hospital & Research Centre, Phase V, Hayatabad, Peshawar, Pakistan. Email: smalam@nwgh.pk*

## ABSTRACT

Spontaneous spinal epidural hematoma (SSEH) is a rare cause of neurological emergency in pregnancy and postpartum period. This complication has previously been published very rarely in the postpartum period. We report the development of spinal epidural hematoma resulting in acute onset paraplegia in a 30 year-old woman after prolonged, assisted vaginal delivery. There was no history of any predisposing factors like coagulopathy, anticoagulation, trauma, vascular anomaly, vasculitis and iatrogenic manipulations such as spinal/epidural anesthesia. Magnetic resonance imaging revealed changes consistent with an epidural hematoma extending from D2-D4. An emergency spinal decompression and laminectomy was done, epidural hematoma was evacuated. Due to delayed recognition and intervention, her neurological functions did not improve significantly.

**Key Words:** epidural hematoma, postpartum period, acute onset paraplegia, assisted vaginal delivery, spinal decompression and laminectomy.

## INTRODUCTION

Spontaneous spinal epidural hematoma (SSEH) is an uncommon neurological complication requiring urgent diagnosis and intervention. Patients with SSEH typically present with acute onset of severe back pain and rapidly developing signs of spinal cord compression or cauda equina. Cases of spontaneous epidural hematoma occurring in pregnancy and postpartum period are exceedingly rare. Very few cases of SSEH in pregnancy and even fewer in postpartum period have been reported in English literature.<sup>1-6</sup> We report the case of a young woman who developed acute onset paraplegia within first week of prolonged, assisted vaginal delivery

generalized hypotonia. Power was 0/5 on right and 3/5 on left side. Reflexes were diminished with upgoing plantars bilaterally. She had loss of sensation of all modalities (superficial and deep) upto D3-D4 spinal segmental level.

An urgent magnetic resonance imaging (MRI) of the thoracic spine was performed, which demonstrated an elliptiform epidural collection (extradural hematoma) located within the posterior spinal canal at D2-D4 level (figures 1 and 2). There was also compression of the adjacent spinal cord, without any signal changes within the cord. There was no radiological evidence of arterio-venous malformation (AVM). Her coagulation profile including bleeding time (BT), clotting time (CT), prothrombin time (PT), activated partial thromboplastin time (APTT) and platelet count were normal. Her RA factor, ANA, viral markers like HBsAg, Anti-HCV antibodies and HIV were negative.

## CASE REPORT

A 23-years-old, G2P1A1 healthy woman, gave birth to her first child after prolonged vaginal delivery that was assisted. Her antenatal period had been uneventful. On fourth postpartum day, she experienced severe pain between her shoulder blades followed by sudden asymmetrical weakness of lower limbs and became bedridden within a day. She was also complaining of urinary retention, constipation and numbness of lower limbs. On admission, she was vitally stable and general physical examination was normal. Her higher mental functions and fundus examination was normal. Motor examination of lower limbs revealed normal bulk with

An urgent neurosurgical consultation was done. Surgical decompression and laminectomy was performed at D3-D4 level; extradural hematoma was drained. There was no evidence of AVM seen peroperatively. Since there was a long window period between the onset of the symptoms and surgical intervention (seventy-two hours), no significant improvement had occurred in clinical status of the patient postoperatively.

## DISCUSSION

Spontaneous spinal epidural hematoma (SSEH) is a rare but potentially devastating neurological condition. It is classified as spontaneous (occurring without apparent cause), or secondary to identifiable source such as coagulopathies, anticoagulant therapies, vascular malformations, trauma, arteritis or iatrogenic conditions such as spinal or epidural injections. Pregnancy and postpartum related epidural hematoma is an even more rare entity and only few documented cases have been reported during pregnancy and postpartum<sup>1-5</sup>.

All the possible underlying predisposing conditions and causes of an epidural hematoma were ruled out by appropriate investigations in our case. There was no relevant history of any trauma to the spine. The development of symptoms, beginning with severe localized radicular pain between shoulder blades, followed by asymmetric lower limb weakness and sensory loss, was consistent with the diagnosis of acute myelopathy and was confirmed as an epidural hematoma within the spinal cord.

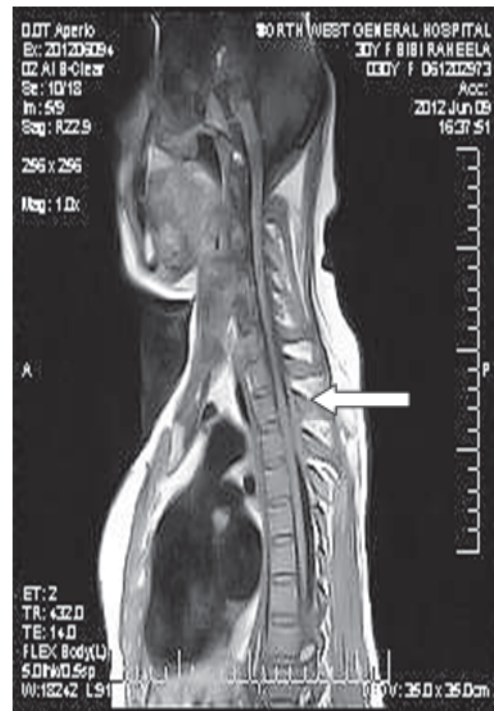
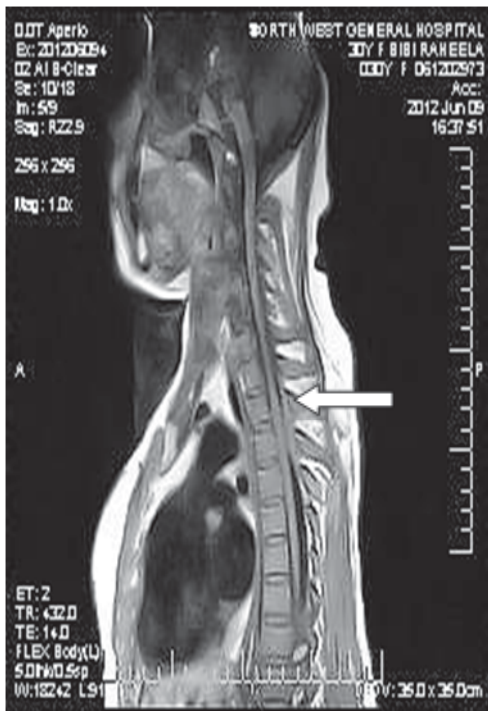
There has been controversy regarding the origin of these hematomas. Most researchers assert that SSEHs arise from the epidural venous plexus in the spinal epidural space. As these veins are valveless, they are unprotected from sudden increase in intra-abdominal or intrathoracic pressure, leading to rupture and hemorrhage<sup>6, 7</sup>. Changes in hormonal levels during pregnancy are responsible for alteration in the vessel wall leading to the hematoma. The epidural venous plexus is mostly prominent in the thoracic spine<sup>7</sup>. The most common site of SSEH is thoracic and cervicothoracic region followed by the thoracolumbar spine<sup>8</sup>.

Spontaneous cervical epidural hematoma (SCEH) is a rare and infrequent cause of spinal cord compression. It usually presents with sudden onset cervical or interscapular pain. Most commonly, as the compression increases, paralysis increases within minutes to hours after the onset of symptoms. A case report of SCEH with sudden onset of severe neck pain and hemiplegia on the left side of the body typically mimicking symptoms of a transient ischemic attack (TIA) was reported from Korea<sup>9</sup>. After thorough investigation, the cervical spine imaging studies revealed acute spinal epidural hematoma in the cervical region. The patient was initially misdiagnosed as TIA. The pain relieved spontaneously within a short time. Such case reports indicate that patients presenting with transient hemiparesis may have SCEH if there is associated severe neck pain and there is no cranial nerve involvement.

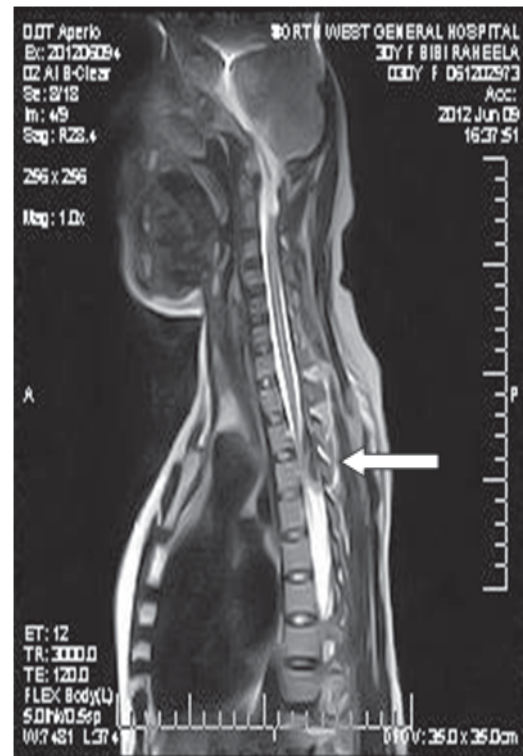
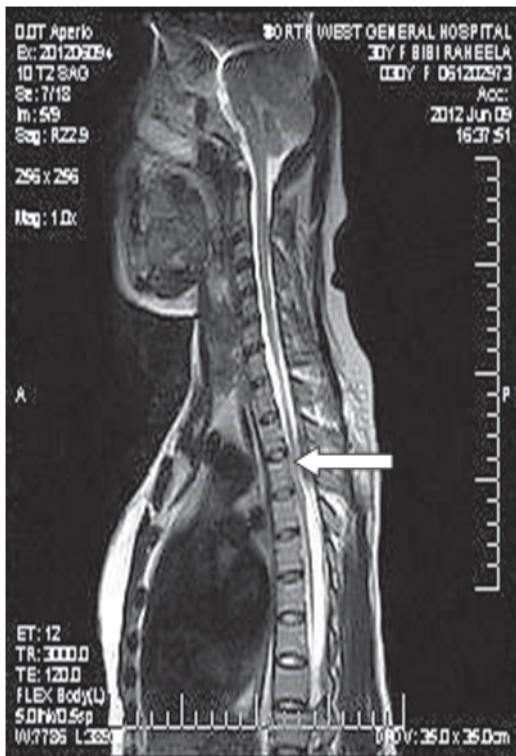Currently MRI is the first choice diagnostic tool for SSEH<sup>10,11</sup>. It typically shows biconvex hematomas in the epidural space with well defined borders tapering superiorly and inferiorly<sup>12</sup>. It also provides information about location, extent of the hematoma, degree of cord compression and is helpful in determining the age of the hematoma<sup>13</sup>. Early surgical intervention including decompression and laminectomy is the treatment of choice for SSEH causing acute compromise of cord function<sup>10</sup>. The results of operative decompression of the spinal cord and subsequent prognosis mainly depend on the duration of the symptoms and the time lost during diagnostic evaluation, and may have negative influence on the functional outcome<sup>14</sup>. Studies have demonstrated most favorable outcomes when a symptomatic hematoma is decompressed within thirty six hours, and some authors suggest even faster intervention, within six hours<sup>14</sup>. Therefore, immediate neuroradiologic confirmation of the clinical diagnosis is necessary<sup>14</sup>. Most patients with SSEH in pregnancy respond to a prompt surgical treatment and generally have a good long term functional recovery<sup>11,15</sup>. There are studies that confirm a relationship between neurologic recovery, the timing of surgery (operation time) and the preoperative neurological status<sup>14</sup>. There is evidence to suggest that functional recovery is better if the preoperative deficit is less severe<sup>14</sup>.

## CONCLUSION

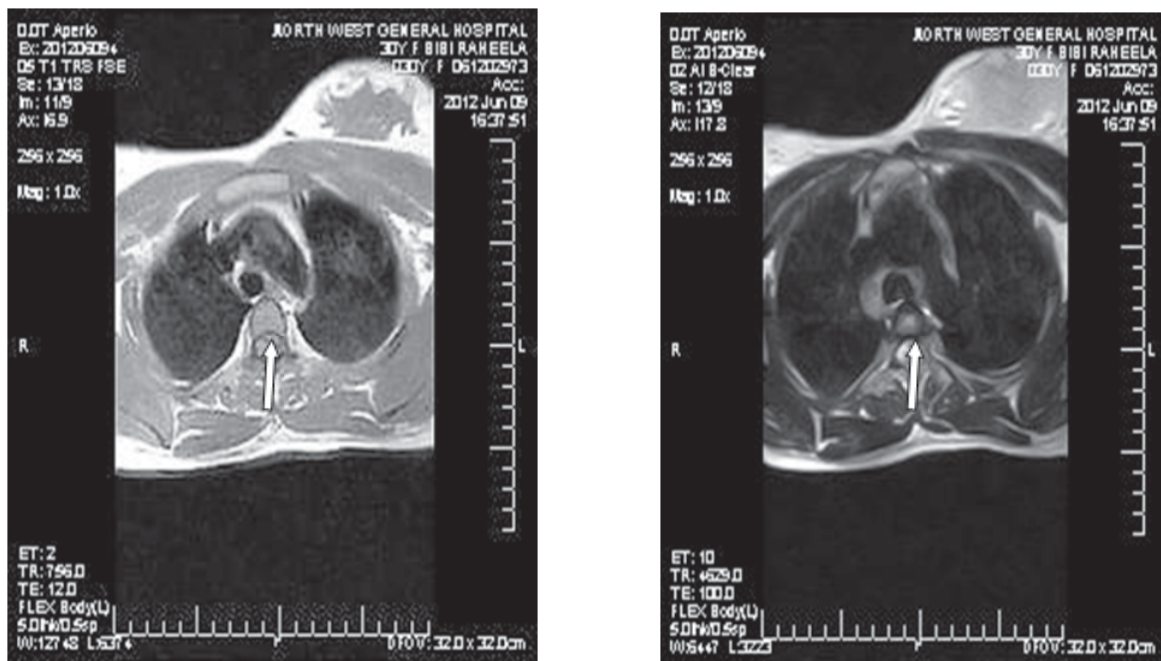
Although SSEH is a rare cause of spinal cord compression in pregnancy and postpartum period, it is essential that the diagnosis is made as early as possible to enable full recovery. MRI plays an especially important diagnostic role. Surgery needs to be performed as soon as possible, because the interval between onset of symptoms and surgery, together with the pre-operative clinical status, determine the clinical outcome.



**Figure 1A:** Sagittal T1 weighted images reveal posterior epidural hematoma located from D2-D4 that is isointense to the spinal cord, causing compression of dorsal cord.



**Figure 1B:** Sagittal T2 weighted images showing heterogeneous epidural collection in the posterior spinal canal.



**Figure 2:** Axial MR images reveal posterior spinal epidural hematoma causing compression on the dorsolateral aspect of the cord that is isointense on T1 and hypointense on T2 weighted images.

## REFERENCES

1. Bidzinski J. Spontaneous spinal epidural hematoma during pregnancy. *J Neurosurg* 1966; 24:1017-8
2. Yonekawa Y, Mehdorn M, Nishikawa M. Spontaneous spinal epidural hematoma during pregnancy. *Surg Neurol* 1975; 3:327-8
3. Carroll S, Malhotra R, Eustace D. Spontaneous spinal extradural hematoma during pregnancy. *J Matern Fetal Med* 1997; 6:218-9
4. Puah KL, Tow BP, Yue WM, Guo CM, Chen JL, Tan SB. Spontaneous cervical spinal epidural hematoma in the postpartum period. *Spine*. 2012; 37:408-10.
5. Bose S, Ali Z, Rath GP, Prabhakar H. Spontaneous Spinal Epidural Hematoma: A Rare Cause of Quadriplegia in the Postpartum Period. *Br J Anaesth* 2007; 99:855-7.
6. Lonjon M, Paquis P, Chanalet S. Nontraumatic spinal epidural hematoma: report of four cases and review of the literature. *Neurosurgery* 1997;1:483-7.
7. Groen R, Groenewegen H, van Alphen A. Morphology of the human internal vertebral venous plexus: a cadaver study after intravenous araldite CY 221 injection. *Anat Rec* 1997; 249:285-94.
8. Fukui M, Swarnkar A, Williams R. Acute spontaneous spinal epidural hematomas. *AJNR* Am J Neuroradiol 1999; 20:1365-72.
9. Lee H, Shin DI, Baek SH, Kang JH, Han HS, Lee SH, et al: Cervical epidural hematoma mimicking a transient ischemic attack: A report of two cases. *J Neurol Asia* 2012; 17 : 169 - 172
10. Matsumura A, Namikawa T, Hashimoto R, Okamoto T, Yanagida I, Hoshi M, et al : Clinical management for spontaneous epidural hematoma : diagnosis and treatment. *Spine J* 2007; 8:534- 37.
11. Song KJ, Lee KB: The poor outcome of the delayed diagnosis of acute spontaneous spinal epidural hematoma: two cases report. *J Korean Med Sci* 2005; 20:331-34.
12. Fujiwara H, Oki K, Momoshima S, Kuribayashi S : PROPELLER diffusion-weighted magnetic resonance imaging of acute spinal epidural hematoma. *Acta Radiol* 2005; 46: 539-42.
13. Holtas S, Heiling M, Lonntoft M. Spontaneous spinal epidural hematoma. Findings at MR imaging and clinical correlation. *Radiology* 1996; 199:409-33.
14. Lawton MT, Porter RW, Heiserman JE, Jacobowitz R, Sonntag VK, Dickman CA. Surgical management of spinal epidural hematoma: relationship between surgical timing and neurological outcome. *J Neurosurg*. 1995; 83:1-7
15. Kelly ME, Beavis RC, Hattings S. Spontaneous spinal epidural hematoma during pregnancy. *Can J Neurol Sci*. 2005; 32:361-5.