

CROSSED CEREBELLAR DIASCHISIS IN PARTIAL STATUS EPILEPTICUS

Sahrish Aieshah Kazi¹, Rehmani Aniqah Jawad², Rashed Nazir³, Shahid Ahmed Shah⁴, Arsalan Ahmad⁵

¹ Postgraduate trainee in Neurology (PGY IV), Division of Neurology, Shifa International Hospital

² Postgraduate trainee in Radiology (PGY IV), Department of Radiology, Shifa International Hospital

³ Assistant Professor Radiology & Consultant Radiologist, Department of Radiology, Shifa International Hospital, and College of Medicine

⁴ Assistant Professor Neurosurgery and Consultant Neurosurgeon, Shifa International Hospital, and College of Medicine

⁵ Associate Professor Neurology and Consultant Neurologist, Shifa International Hospital, and College of Medicine

Correspondence to: Sahrish Aieshah Kazi MBBS Postgraduate trainee in Neurology (PGY IV), Division of Neurology, Shifa International Hospital, Shifa Tameer-e-Millat University, H-8/4, Islamabad.
Email: aieshah.sahrish@gmail.com.

ABSTRACT

Crossed cerebellar diaschisis is a phenomena described as decrease in metabolism in the cerebellar hemisphere contralateral to the supratentorial lesion. A 61 year old man presented with status epilepticus. CT Brain showed small acute hemorrhage in left parietal lobe. MRI revealed diffusion restriction in right cerebral and left cerebellar hemispheres with hyperintensities on T2WI and FLAIR. However, CT perfusion was suggestive of increased perfusion in these areas. Periictal EEG showed frequent bursts of higher voltage spike and wave discharges over the right hemisphere. He was treated with IV antiepileptics. But he continued to deteriorate, and expired at 10th day of admission.

INTRODUCTION

Crossed cerebellar diaschisis (CCD) is phenomena observed on ictal/postictal imaging in epilepsy patients. Increased synaptic activity observed during seizures causes increase energy metabolism and cerebral hyperperfusion. CCD in status epilepticus is thought to be due to excessive transmission of excitatory activity to cerebellum via cortico-ponto-cerebellar pathway. We report this phenomenon in patient presenting with complex partial status epilepticus undergoing MRI and further investigated by CT perfusion.

CASE REPORT

A 61 year old gentleman, with history of hypertension and right thalamic bleed in 2001, presented to ER in status epilepticus. On examination, he was a well-developed elderly gentleman of average height and built lying in bed having jerking of upper and lower limbs. His Blood pressure was 230/120mmHg and GCS 8/15 (E1V2M5). Pupils were 4 mm, symmetrical and bilaterally reactive to light. Eyes were deviated to left. Tone and reflexes were markedly increased on the left side. Plantars were bilaterally flexors. The patient was admitted and managed with IV diazepam, phenytoin, valproic acid and levetiracetam. An unenhanced CT brain done in ER showed a 1.8 × 1.3cm acute intraparenchymal hemorrhage in left parietal lobe and encephalomalacia in right basal ganglia due to old stroke. A periictal EEG (Figure 1) showed frequent bursts of higher voltage spike and wave discharges with a higher voltage seen over the right hemisphere, occurring in continuous runs. The sharp waves and slow waves activity also coincided with clinical myoclonic like jerks of the limbs. There was attenuation of this sharp and slow wave activity on giving intravenous diazepam. MRI Brain with contrast was performed. Diffusion weighted images (DWI) showed hyperintense signal in right fronto-parieto-occipital lobes and left cerebellar hemisphere; with a corresponding decrease in ADC map. These areas were bright on T2WI and fluid attenuated inverse recovery sequences (FLAIR). CT brain perfusion imaging showed mildly increased perfusion in right cerebral and left cerebellar hemispheres with increased Cerebral Blood Volume (CBV) & Cerebral Blood Flow (CBF) and decreased Mean Transit Time (MTT), TTP and delayed maps. CT Angiogram (CTA) brain was normal without vascular stenosis, malformations or aneurysm. Dural sinuses were patent and there was no evidence of dural sinus thrombosis. On the basis of his radiological findings he was diagnosed as crossed cerebellar diaschisis secondary to partial status epilepticus. His seizure activity gradually improved. However he had resistant hypertension, requiring higher doses of IV glyceryltrinitrate followed by multiple oral antihypertensives. He continued to deteriorate. At 8th day postadmission, his oxygen saturations started to drop. Family opted for DNR status. On 10th day post admission, he went into asystole and expired.

DISCUSSION

Crossed cerebellar diaschisis (CCD) is a phenomenon first reported by von Monakow in 1914 as a transient impairment of functional activity in an area remote from the site of primary brain lesion.¹ The first radiological proof of it was produced by Baron et al in 1980 by PET scan in which case it is attributed to hypometabolism and cerebral perfusion affecting afferent cortico-ponto-cerebellar pathway which results in decreased blood flow and metabolism in cerebellar hemisphere contralateral to supratentorial lesion.^{2,3} The first document of this phenomenon in epilepsy was reported in 1992 in intractable complex partial seizures.³ The exact pathophysiology of CCD in status epilepticus (SE) is not known. It is established that the increased synaptic activity during seizures increases blood flow and metabolism in cerebral cortex.¹ Cerebral cortex is connected to the contralateral cerebellum via cortico-ponto-cerebellar pathway. Prolonged synaptic activity via these fibers results in neuronal damage which may manifest radiologically in the form of crossed cerebellar diaschisis.⁵ It may lead to cytotoxic injury and will appear on DWI as diffusion restriction. However, CT perfusion revealed hyperperfusion in these areas. We know the cerebellum has an inhibitory role in epilepsy through release of inhibitory neurotransmitter GABA from Purkinje cells and Purkinje loss is a morphologic feature of severe epilepsy with generalized convulsions. The loss of Purkinje might be explained by an increase in demand of inhibition resulting in GABA depletion and increased influx of calcium in neurons until toxic levels are reached.^{6,7} Unfortunately, the patient didn't recover. We have no follow up study to determine the reversibility of the radiological phenomena as reported in literature.

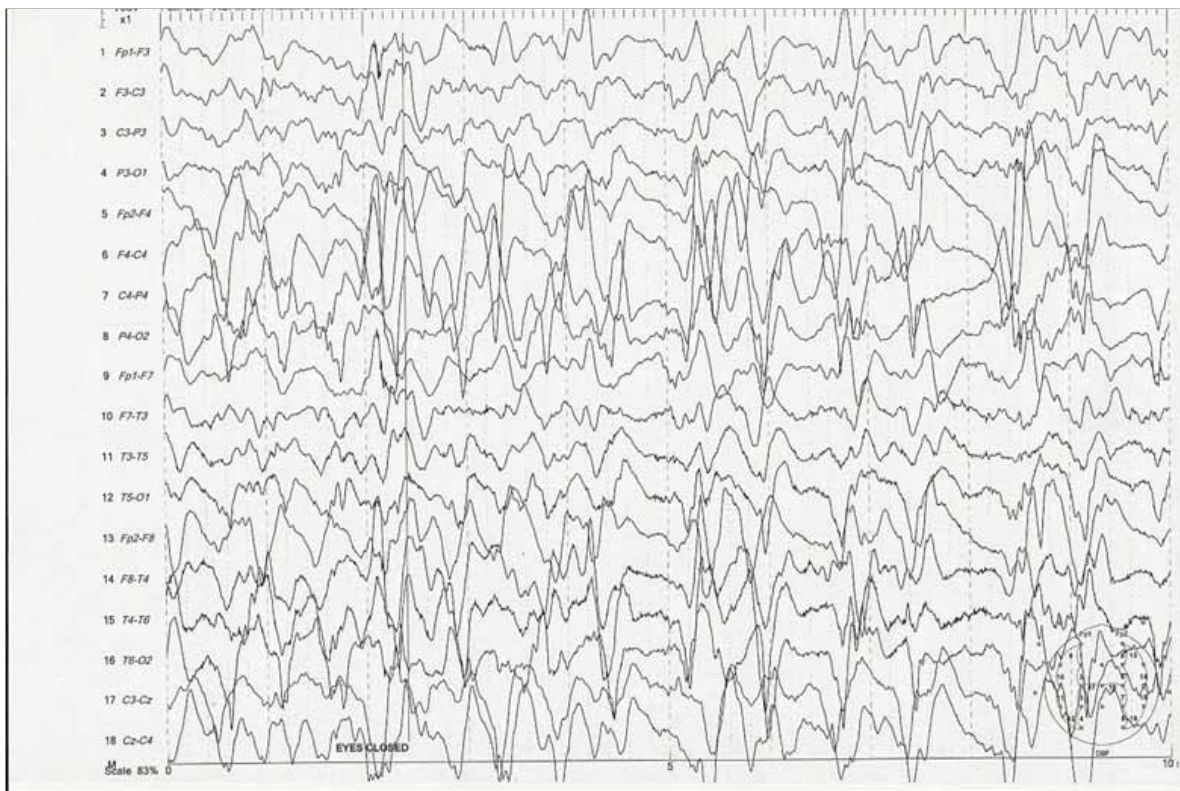


Figure1. Periictal EEG showing continuous bursts of spike and wave discharges over right hemisphere

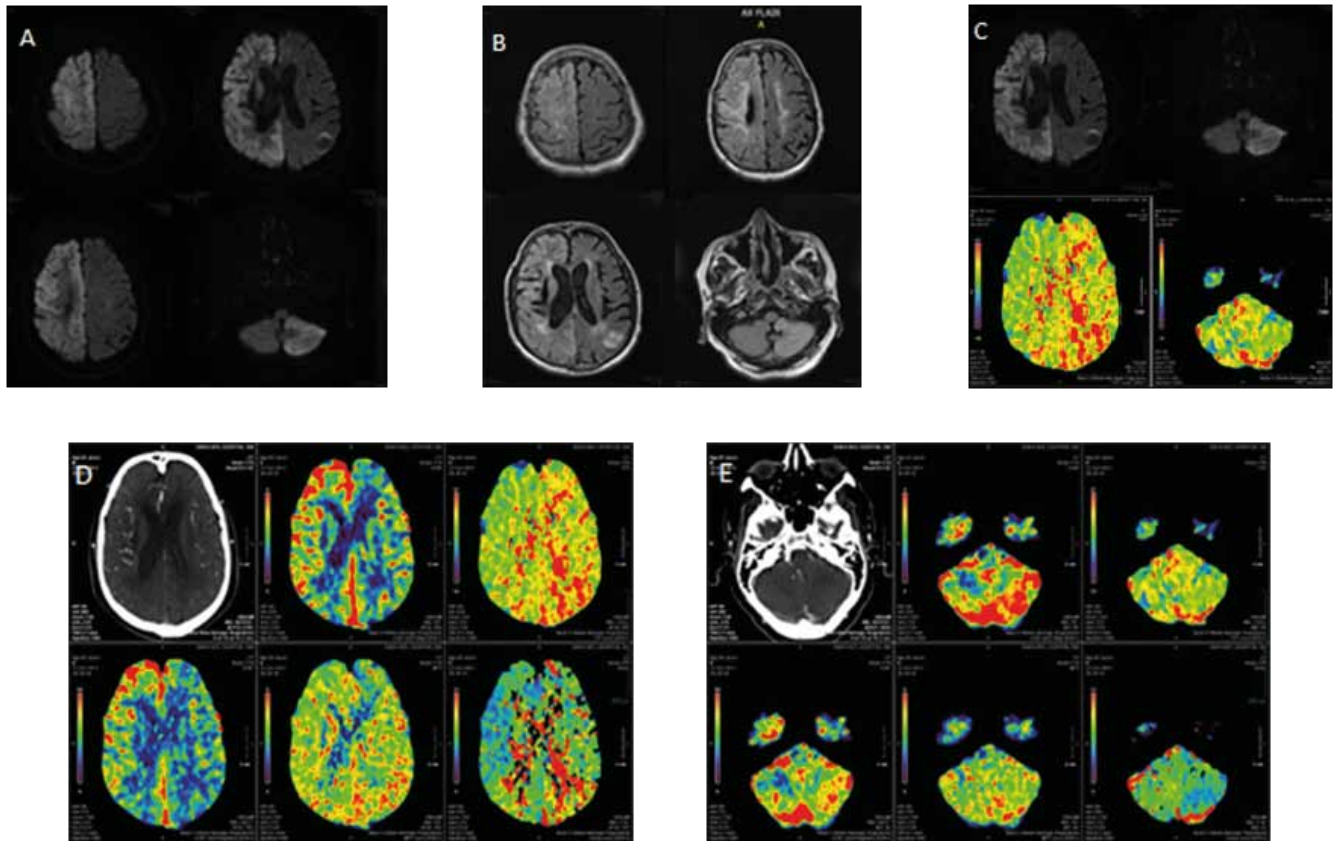


Figure 2. MRI revealed diffusion restriction [A] in right cerebral and left cerebellar hemispheres with hyperintense signal on FLAIR [B]. Corresponding DWI and CT Perfusion Images [C]. CT perfusion increased CBV & CBF and decreased MTT, TTP and delayed maps in right cerebral [D] and left cerebellar hemispheres [E], suggestive of increased perfusion.

REFERENCES

1. Tien, RD, Ashdown, BC. Crossed Cerebellar Diaschisis and Crossed Cerebellar Atrophy: Correlation of MR Findings, Clinical Symptoms, and Supratentorial Diseases in 26 Patients. *AJR* May 1992, 158:1155-1159
2. Ogasawara, Kuniaki, Masakazu Kobayashi, et al. "Significance of postoperative crossed cerebellar hypoperfusion in patients with cerebral hyperperfusion following carotid endarterectomy: SPECT study." *European journal of nuclear medicine and molecular imaging* 35, no. 1 (2008): 146-152.
3. Baron, J. C., M. G. Bousser, D. Comar, and P. Castaigne. "Crossed cerebellar diaschisis" in human supratentorial brain infarction." *Transactions of the American Neurological Association* 105 (1981): 459.
4. Park CH, Kim SM, Streletz LJ, Zhang J, Intenzo C. Reverse crossed cerebellar diaschisis in partial complex seizure related to herpes simplex encephalitis. *ClinNucl M* 1992 Sep;17(9):732-5
5. Samaniego, Edgar A., Erika Stuckert, Nancy Fischbein, and Christine AC Wijman. "Crossed cerebellar diaschisis in status epilepticus." *Neurocritical care* 12, no. 1 (2010): 88-90.
6. Wieshmann, U. C., M. R. Symms, and S. D. Shorvon. "Diffusion changes in status epilepticus." *Lancet* 350.9076 (1997): 493.
7. Men, Suleyman, Donald H. Lee, Jane R. Barron, and David G. Muñoz. "Selective neuronal necrosis associated with status epilepticus: MR findings." *American journal of neuroradiology* 21, no. 10 (2000): 1837-1840.