

# SPORADIC CJD AND RETINITIS PUNCTATA ALBESCENS- A CASE REPORT AND LITERATURE REVIEW

Quratulain Khan, Yusra Hanif Khan

Correspondence to: Quratulain Khan, Department of Psychiatry, Aga Khan University, Karachi. Email: Qurat.khan@aku.edu  
Date of submission: June 28, 2014, Date of revision: August 20, 2014, Date of acceptance: August 22, 2014

## ABSTRACT

**Introduction** Sporadic Creutzfeldt-Jakob disease (sCJD) is the most common form of CJD causing 85% of all cases. Various phenotypes of sCJD have been identified including Heidenhain variant which has early and predominant visual symptoms with most pronounced neuropathological changes in occipital lobe. **Methodology.** We are reporting a case of sCJD with Retinitis Punctata Albescens (RPA), a variant of Retinitis Pigmentosa (RP), which to our knowledge has not been reported before. A 51 year old, married, right handed, Pakistani woman presented with dementia and gait problems for 3 months and visual hallucinations for 2 months. Ophthalmological examination 3 years prior to current presentation scattered white dots on the retina in both eyes centrally and peripherally and a diagnosis of retinitis punctata albescens (RPA) was made. MRI brain showed T2 hyperintensities and restricted diffusion on DWI in frontal, parietal and temporal cortices as well as caudate and putamen bilaterally. EEG showed slow posterior background activity and poorly formed tri-phasic waves. We diagnosed probable sCJD using the 1998 WHO criteria. Patient also met UCSF sCJD criteria. **Discussion.** Visual symptoms in sCJD are more commonly associated with posterior cortical pathology and less commonly with retinal pathology. However this is an isolated case report and warrants validation.

## INTRODUCTION

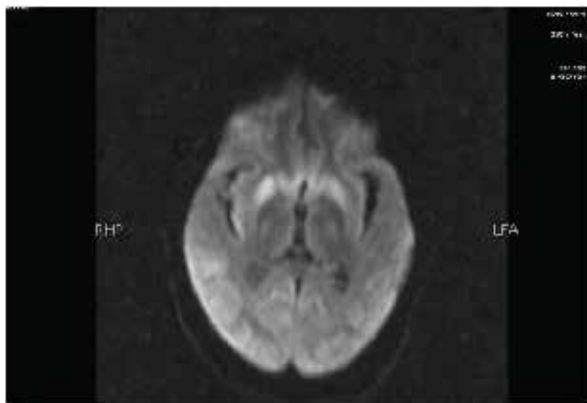
Sporadic Creutzfeldt-Jakob disease (sCJD) is the most common form of CJD causing 85% of all Cases<sup>(1)</sup>. Various phenotypes of sCJD have been identified including Heidenhain variant which has early and predominant visual symptoms with most pronounced neuropathological changes in occipital lobe. Visual symptoms may include blurred vision, decreased visual acuity, visual field restriction, metamorphopsia, disturbed color perception, visual hallucinations, optical anosognosia, palinopsia, tunnel vision and cortical blindness<sup>(2)</sup>. We are reporting a case of sCJD with Retinitis Punctata Albescens (RPA), a variant of Retinitis Pigmentosa (RP), which to our knowledge has not been reported before. RPA is an autosomal recessive, progressive rod-cone dystrophy that is characterized by white punctata throughout the fundus with degenerative changes mainly in the outer retinal layer.<sup>(3)</sup> This case report was exempted by the Aga Khan University Ethical Review Committee (ERC) for full review as it does not involve direct intervention of human subjects.

## CASE PRESENTATION

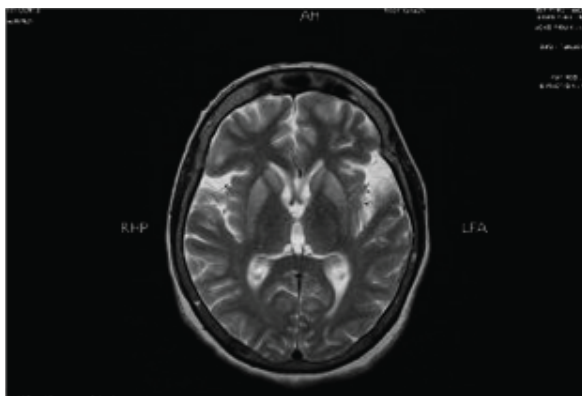
A 51 year old, married, right handed, Pakistani woman presented with dementia and gait problems for 3 months and visual hallucinations for 2 months.

Her thought process was slow with inability to remember names of family members. She had difficulty initiating gait, had sustained 2 falls, and was experiencing vivid images of deceased family members, children and animals. Family also reported lack of interest and decreased oral intake. Past medical history was significant for diabetes mellitus. In addition she had progressive night blindness for 8 years. Ophthalmological examination 3 years prior to current presentation showed near vision of 20/50 in both eyes with bilateral posterior subcapsular cataracts. Examination of pupil and pupillary reflexes, extra-ocular movements, cornea, conjunctiva and anterior chamber was unremarkable. Fundoscopy showed scattered white dots on the retina in both eyes centrally and peripherally and a diagnosis of retinitis punctata albescens (RPA) was made. There was no history of surgeries, invasive procedures, exogenous hormones, blood transfusions or international travel and no prior psychiatric history. Family history was significant for Japanese B encephalitis in daughter 3 years ago. Initially she was diagnosed with depression and started on escitalopram, mirtazapine and Inderal. After a few days combination of levodopa/carbidopa was added for suspected Parkinson's plus syndrome but was stopped due to visual hallucinations and worsening rigidity and ropinirole, risperidone and procyclidine were prescribed. However symptoms persisted and she was admitted to neurology unit. On

examination by our psychiatry team she was persistently smiling, with incomprehensible speech. Mini mental status exam could not be performed and she was not oriented to time, place and person. On neurological examination gait was parkinsonian with short steps, reduced arm swing, and stooped posture. Fine rest tremor was present in both hands. Tone was increased in upper limbs bilaterally with intact power. Reflexes were +3 in all limbs and plantars were flexor bilaterally. Myoclonic jerks were present in upper limbs. Work up revealed normal blood counts, serum creatinine, electrolytes, thyroid profile, INR, vitamin B 12, CRP, ceruloplasmin, urine DR and urinary copper levels. ESR was 36 and CPK was 395. CT chest, abdomen and pelvis with contrast were unremarkable. MRI brain showed T2 hyperintensities and restricted diffusion on DWI in frontal, parietal and temporal cortices as well as hyperintense signals in caudate and putamen bilaterally on T2 without gadolinium enhancement with associated FLAIR signal change in the same regions (Fig 1, Fig 2). EEG showed slow posterior background activity and poorly formed tri-phasic waves. CSF glucose, protein, leucocyte and RBC counts were unremarkable. Gram stain, fungal smear, cryptococcal antigen and cytology for malignancy were negative. CSF autoantibodies and



**Fig 1**



**Fig 2**

14-3-3 were not tested due to unavailability of the tests in Pakistan. We diagnosed probable sCJD using the 1998 WHO criteria (4). Patient also met UCSF sCJD criteria (5).

## DISCUSSION

Retinal involvement has been shown in sCJD previously. Although centrifugal spread of abnormal prion protein (PrP<sup>Sc</sup>) has been discussed more, CJD has been attributed to corneal grafting (6). Presence of RP in this patient with no family history of RP generated considerable interest for us; this may just be a coincidence however an interesting one. One case report of histopathologically proven CJD related to familial RP was published in 1988 by Mitrova (7).

## CONCLUSION

Visual symptoms in sCJD are more commonly associated with posterior cortical pathology and less commonly with retinal pathology. It would be helpful to keep in mind possible association with retinal disease. However this is an isolated case report and warrants validation.

## REFERENCES

1. Muayqil T et al Evidence-based guideline: Diagnostic accuracy of CSF 14-3-3 protein in sporadic Creutzfeldt-Jakob disease Report of the Guideline Development Subcommittee of the American Academy of Neurology *Neurolog*® 2012;79: 1499–1506
2. Cooper S A et al Isolated visual symptoms at onset in sporadic Creutzfeldt- Jakob disease: the clinical phenotype of the “Heidenhain variant” *Br J Ophthalmol* 2005;89:1341–1342
3. Novel Mutation in RLBP1 Gene in a Japanese Patient With Retinitis Punctata Albescens. Makoto Nakamura, MD, Jian Lin, MD, Yasuki to, MD, and Yozo Miyake, MD *Am J Ophthalmol* 2005;139:1133–1135
4. World Health Organization: Emerging and other communicable diseases, surveillance and control. WHO; Geneva: Feb 9-11. 1998 WHO Global surveillance, diagnosis and therapy of human transmissible spongiform encephalopathies: Report of a WHO consultation
5. Young GS, Geschwind MD, Fischbein NJ, et al. Diffusion-weighted and fluid-attenuated inversion recovery imaging in Creutzfeldt-Jakob disease: high sensitivity and specificity for diagnosis. *AJNR Am J Neuroradiol* 2005;26:1551–1562
6. Prion Protein Accumulation in Eyes of Patients with Sporadic and Variant Creutzfeldt-Jakob

- 
- Disease Mark W. Head, Victoria Northcott, Kathleen Rennison et al, Investigative Ophthalmology & Visual Science, January 2003, Vol. 44, No. 1
7. A case of Creutzfeldt-Jakob disease related to familial retinitis pigmentosa patients. E.Mitrova. European J of Epd March 1988, Volume 4, Issue 1, pp 55-59

**Conflict of Interest:** Author declares no conflict of interest.

**Funding Disclosure:** Nil

**Author's Contribution:**

**Dr. Quratulaian Khan:** Study concept and design, protocol writing, data collection, data analysis, manuscript writing, manuscript review

**Dr. Yusra Hanif Khan:** Data collection, data analysis, manuscript writing, manuscript review