

# EFFECTIVENESS OF STRETCHING OF THE FLEXOR RETINACULUM WITH ULTRASONIC THERAPY IN THE MANAGEMENT OF CARPAL TUNNEL SYNDROME

Waqar Ahmed Awan<sup>1</sup>, Muhammad Naveed Babur<sup>2</sup>, Misha Ansari<sup>3</sup>, Maria Liaqat<sup>4</sup>

<sup>1</sup>Assistant Professor, IIRS, Isra University Islamabad Campus

<sup>2</sup>Associate Professor, IIRS, Isra University Islamabad Campus

<sup>3</sup>Lecturer, IIRS, Isra University Islamabad Campus

<sup>4</sup>Research Associate, IIRS, Isra University Islamabad Campus

**Correspondence to:** Muhammad Naveed Babur Email: naveed.babur@isra.edu.pk

**Date of submission:** May 28, 2014, **Date of revision:** July 17, 2014, **Date of acceptance:** August 22, 2014

## ABSTRACT

**Aims & Objective:** The objective of study was to compare the effectiveness of manual stretching of the flexor retinaculum with or without ultrasonic therapy. **Methods:** The study was started by selecting the 50 patients from the out patients department of Al-nafees Hospital AlipurFarash and National institute of Rehabilitation Medicine Islamabad with history of carpal tunnel syndrome. The 25 patients in experimental group were treated with manual stretching of flexor retinaculum and ultrasound and 25 patients of control group were treated with manual stretching of flexor retinaculum. Every session was started by assessment of improvement of the symptoms in each patient. Data was collected through Numeric pain rating scale, point Paresthesia assessment scale and muscle strength by hydraulic hand dynamometer. Independent sample t-test was used to analyze the data with  $p \leq 0.05$ . **Results:** The mean age of subjects was  $1.78 \pm 0.64$  and 41 subjects have CTS of Right hand remaining 9 subjects were left handed. After the completion of the treatment program it was observe that there was no difference in the effectiveness of manual Stretching of flexor retinaculum with ultra sound therapy and manual stretching of flexor retinaculum alone. The NPRS, paresthesia and muscle stretch showed  $p \geq 0.05$  between experimental and control groups. **Conclusion:** This study proved that manual stretching of the flexor retinaculum along with ultra sonic therapy have same affects as manual stretching of the flexor retinaculum alone.

**Key Words:** Carpal tunnel syndrome, Ultrasound therapy, Stretching exercises, Manual therapy Paresthesia.

## INTRODUCTION

The median nerve entrapment in the carpal tunnel is the condition known as Carpal tunnel syndrome (CTS). The symptoms of the CTS are numbness, parasthesia, and pain where median nerve supplies. In 1854, Sir James Paget first reported median nerve entrapment after the fracture of distal radius<sup>(1)</sup>. In 1880, the first series of the patients with pain and paresthesia in the area of distribution of median nerve were presented by James Putnam<sup>(2,3)</sup>. Whenever there is inflammation it causes compression of median nerve in the carpal tunnel and results in pain, numbness, paresthesia and weakness of the muscle of thenar eminence in the lateral 3 and ½ fingers<sup>(2)</sup>. Carpal tunnel syndrome is more common in female and in dominant hand. The carpal tunnel syndrome is common in occupations like manufacturing, sewing, finishing, cleaning, meat, poultry and fish packing. In one study conducted in 2001 by the Mayo Clinic showed that the people who work on computer for more than 7 hours a day do not have any risk of developing CTS<sup>(4)</sup>. There are multiple factors contributing in the etiology of carpal tunnel syndrome (CTS) including local

and systemic factors. The Conditions like alcoholism, renal failure with hemodialysis, mucopolysaccharidoses are also related to CTS<sup>(2)</sup>. The elevated pressure in the carpal tunnel causes the compression of median nerve. Callus formed by the Fracture, bony over growth, abnormal muscle mass, neoplasms, inflamed synovial membrane and infection, along with gout and other inflammatory conditions, can lead to high pressure within the carpal tunnel leading to CTS. Some time Direct pressure and extreme range of wrist flexion and extension can lead to further increase in sensory and motor block.<sup>(2,3)</sup> There are several clinical tests used to diagnose the CTS. Some provoking and electro diagnostic test for CTS includes Phalen test, Tinel's sign test and Carpal compression test<sup>(5,6)</sup>. The use of physiotherapy modalities (in particular therapeutic ultrasound) may provide short-term relief in some patients<sup>(7,8,9)</sup>. Awan WA etal. 2012 describe a case report the application of manual mobilization of flexor retinaculum along with inter carpal joint mobilization have a role in reducing the symptoms in carpal tunnel syndrome<sup>(10)</sup>. In physical therapy management of carpal tunnel syndrome the ultrasonic therapy in used in conjunction with manual

mobilization of flexor retinaculum. Therapeutic ultrasound is a modality that produces acoustical high-frequency vibrations with both thermal and nonthermal effects <sup>(11)</sup>. Deep, pulsed ultrasound over the carpal tunnel for 15 min for 20 treatments decreases pain and paresthesia symptoms, reduces sensory loss, and improves median nerve conduction and strength when compared with sham ultrasound <sup>(12)</sup>. The study was conducted to find the better treatment option for the management of carpal tunnel syndrome and study will help minimize the cost of the treatment also reduce the duration of treatment.

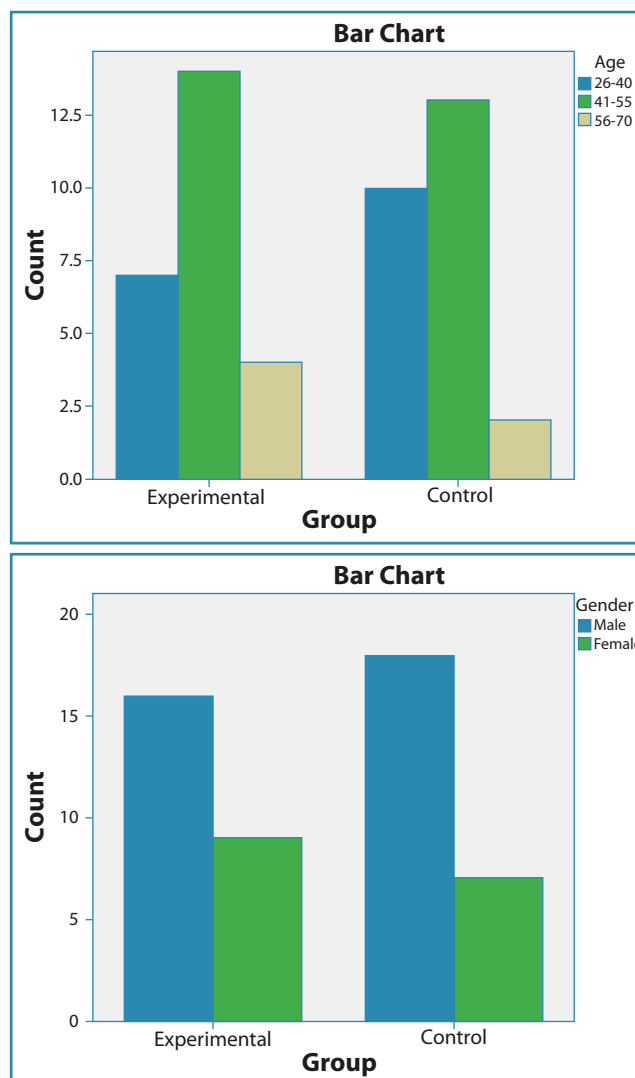
## METHODOLOGY

The study was conducted in Al-nafees Hospital AlipurFarash, National institute of Rehabilitation Medicine Islamabad and 50 patients were selected by the primary author from the out patients department with the history of carpal tunnel syndrome. Patients having idiopathic carpal tunnel syndrome were included in this study. All the patients were diagnosed clinically by performing Tinel's test and phalens test for CTS. Patients having positivetinel sign and phalens test were included in this study <sup>(18)</sup>. Phalen's maneuver is performed by flexing the wrist gently as far as possible, then holding this position and awaiting symptoms.<sup>(17)</sup> A positive test is one that results in numbness in the median nerve distribution when holding the wrist in acute flexion position within 60 seconds. The quicker the numbness starts, the more advanced the condition. Tinel's test is performed by lightly tapping the skin over the flexor retinaculum to elicit a sensation of tingling or "pins and needles" in the nerve distribution. The study indicated that Phalen's test can be used in absence of NCS for the diagnosis of CTS and it is more specific and sensitive than Tinel's test. <sup>(17,18)</sup> The patients were allocated to different groups by using simple random sampling technique. The 25 patients in experimental group were treated with stretching of flexor retinaculum and ultrasound while 25 patients in control group were treated only with stretching of flexor retinaculum. Every treatment session was started by documenting the improvement in symptoms. Data was collected through Numeric pain rating scale, 3 point Paresthesia assessment scale and muscle strength was measured by hydraulic hand dynamometer. Baseline data was interpreted in term of bar charts and Independent sample t-test was used to analyze the data with  $p \leq 0.05$ .

## RESULTS

In the study 50 subjects of both genders were included ( $1.32 \pm 0.47$ ). The mean age of subjects was

$1.78 \pm 0.64$  and 41 subject have CTS of Right hand remaining 9 subjects were left handed ( $1.30 \pm 0.46$ ). The figure 1a&1b both showed that data was normally distributed in both control and experimental group.



**Figure 1a & 1b:** Allocation of subjects in Groups (Age & Gender)

This study found that there was a statistically difference in the effectiveness of stretching of the flexor retinaculum with or without ultrasonic therapy. The NPRS showed mean and standard deviation of experimental group ( $0.000 \pm 0.0000$ ). The mean and standard deviation of control group ( $0.120 \pm 0.6000$ ) and  $p=0.12$ . While considering paresthesia mean and standard deviation in experimental group ( $0.080 \pm 0.276$ ) and in control group ( $0.280 \pm 0.678$ ) and  $p = 0.09$ . While considering muscle strength mean and standard deviation in experimental group ( $3.20 \pm 0.408$ ) and in control group ( $3.28 \pm 0.541$ ) and  $p = 0.16$ . (Table 1)

The result in the table 1 showed p-value for all variables is  $p > 0.05$

|                                  | Group        | N  | Mean | Std. Deviation | p-value |
|----------------------------------|--------------|----|------|----------------|---------|
| Numeric Pain Rating Scale (NPRS) | Experimental | 25 | .000 | .0000          | 0.12    |
|                                  | Control      |    | .120 | .6000          |         |
| Paresthesia                      | Experimental | 25 | .080 | .276           | 0.09    |
|                                  | Control      |    | .280 | .678           |         |
| Muscle Strength                  | Experimental | 25 | 3.20 | .408           | 0.16    |
|                                  | Control      |    | 3.28 | .541           |         |

## DISCUSSION

In physical therapy the management options for CTS include ultrasound therapy along with sustained stretching of median nerve and tight musculature and strengthening exercises for the weak muscles of the hands<sup>(5,10)</sup>. Those patients who have been considered for surgery, the techniques of mobilizations and stretching of median nerve and tight muscles of wrist has already been proven to be ineffective in CTS management<sup>(7)</sup>. 71% of the patients went for surgery because they were not offered gliding exercises and only 43% of the patients need surgical treatment instead they were offered by gliding technique. During the treatment session of CTS special care should be taken because speed and the frequency of force of the exercises can exacerbate the symptoms<sup>(8)</sup>. The nerve conduction studies established that ultrasound was beneficial to patients with CTS. The usage of different therapeutic modalities including ultrasound therapy, phonophoresis and iontophoresis, may or may not provide relief in some patients with CTS<sup>(5)</sup>. Stretching of flexor retinaculum with various techniques made it possible to reduce compression in the carpal tunnel<sup>(10)</sup>. This study includes longitudinal fibers stretching of the flexor retinaculum along with ultrasound therapy. The primary author treated the patients, allocated to experimental group with longitudinal fibers stretching along with ultrasound therapy, with the similar basic protocol as appointed for the patients allocated to control group in which only longitudinal fibers stretching exercises were unified. In the experimental group prior to stretching exercises ultrasonic therapy was done with 0.75w/cm<sup>2</sup> (Pulsed) for 5 minutes. Stretching was done by the primary author to break down adhesion or scar tissue in the areas of carpal tunnel. During the session patients rested their forearm-wrist-hand on the edge of treatment table and the primary author applied stretches to the flexor retinaculum with the help of thear eminences of both hands and figures. The result showed

remarkable improvement in experimental group in which both manual therapy and ultrasound were used. The patients treated with manual therapy alone were not shown significant improvement. The treatment sessions were also obviously reduced in the both groups but on the other hand in control group were treated for more than three weeks. The main reason behind that was not clearly understood. The researcher considered this due to improper following of instruction given to the patients for home exercise program. Although stretching that is specific to nerve and different strengthening exercises of weakened muscles of hand and wrist proven to exacerbate symptoms in CTS but pros and cons showed that these are still helpful for normal excursion of hand and wrist for strengthening of muscles. Massage and nerve glide techniques still proved their beneficial effects in patients with CTS.<sup>(9,10)</sup> The ergonomics of the workplace of the patient should also be assessed to avoid protracted hand use at the end of joint range. Extreme flexion and extension at wrist increases pressure in the carpal tunnel, so adjustment of work tool height can reduce symptoms to some extent.<sup>(14,15,16)</sup>

## CONCLUSION

This study proved that manual stretching of the flexor retinaculum along with ultra sonic therapy is more effective than manual stretching of the flexor retinaculum alone. So it is recommended that manual stretching of flexor retinaculum must be use along with ultrasonic therapy in the management of the CTS' symptoms. It is also suggested that along with age and gender baseline data must be consider in regard of hand involvement (Dominant) and occupation. Because these two variables were missing in the study, it may affect the results. So generalizability of the results may be questioned. It is also very important for the therapist to teach the self mobilization of flexor retinaculum and home program to avoid symptom CTS to reappear.

## REFERENCES

1. Nigel L Ashworth, Carpal Tunnel Syndrome. eMedicine. Dec. 4, 2008.
2. David A Fuller, Carpal Tunnel Syndrome. eMedicine. Aug 12, 2008
3. Lundborg G, Dahlin LB. The pathophysiology of nerve compression. *Hand. Clin.* May 1992; 8:215-27.
4. SomaiahAroori, Roy AJ Spence, Carpal Tunnel Syndrome, *Ulster Med J* 2008; 77 (1) 6-17
5. Banta CA. A Prospective, Nonrandomized Study of Iontophoresis, Wrist Splinting, And Anti-inflammatory Medication in the Treatment of Early-Mild Carpal Tunnel Syndrome. *J Occup Med.* Feb 1994;36(2):166-8
6. Chang MH, Lee YC, Hsieh PF. The Real Role of Forearm Mixed Nerve Conduction Velocity in the Assessment of Proximal Forearm Conduction Slowing In Carpal Tunnel Syndrome. *J ClinNeuro physiol.* Nov 6 2008;
7. DarlinHertling and Randolph M. Kessler. Management of Common Musculoskeletal Disorders. 3rd Edition. 1996:265-370
8. Rozmaryn, L.M, Dovelle, S, Rothman, E.R., et al, 1998. Nerve and Tendon Gliding Exercises and the Conservative Management of Carpal Tunnel Syndrome, *Journal of Hand Therapy* 11,171–179.
9. Akalin E, El O, Peker O, Senocak O, Tamci S, Gülbahar S, Cakmur R, Oncel S. Treatment of carpal tunnel syndrome with nerve and tendon gliding exercises. *Am J Phys Med Rehabil.* 2002 Feb;81(2):108-13.
10. Awan WA, Babur MN. Manual mobilization and electrotherapy can manage the symptoms of carpal tunnel syndrome. *RMJ.* (2012), 37(2): 222-223.
11. Osterman AL, Whitman M, Porta LD. Nonoperative carpal tunnel syndrome treatment. *Hand Clin.* 2002;18:279–289.
12. Hans Carlson, Agatha Colbert,Current options for nonsurgical management of carpal tunnel syndrome: *Int J ClinRheumtol.* Feb 2010; 5(1): 129–142
13. Pal, J. Morris, J. Keenan, P. Mangion, Management of idiopathic carpal tunnel syndrome (ICTS):A Survey of Rheumatologists Practice and Proposed Guidelines, *British Journal of Rheumatology* 1997;36:1328-1330
14. Kao SY. Carpal Tunnel Syndrome as an Occupational Disease. *J Am Board FamPract.* Nov-Dec 2003, 16(6):533-542.
15. Page MJ, Massy-Westropp N, O'Connor D, Pitt V. Splinting for carpal tunnel syndrome. *Cochrane Database Syst Rev.* Jul 11 2012; 7:CD010003.
16. Ugurlu U, Ozkan M, Ozdogan H. The development of a new orthosis (neuro-orthosis) for patients with carpal tunnel syndrome: its effect on the function and strength of the hand. *ProsthetOrthot Int.* Dec 2008; 32(4):403-21.
17. Cush JJ, Lipsky PE. Approach to articular and musculoskeletal disorders. *Harrison's Principles of Internal Medicine.* 2004. 16th ed. McGraw-H-ill Professional. p. 2035.ISBN 0-07-140235-7.
18. Khalid A.O.Al-Dabbagh, Shorsh Ahmad Mohamad. Sensitivity and Specificity of Phalen's Test and Tinel's Test in Patients with Carpal Tunnel Syndrome. *Diyala Journal of Medicine.* 2013: 5(1): 1-14

**Conflict of Interest:** Author declares no conflict of interest.

**Funding Disclosure:** Nil

**Author's Contribution:**

**Waqar Ahmed Awan:** Study concept and design, protocol writing, data collection, data analysis, manuscript writing, manuscript review

**Muhammad Naveed Babur:** Study concept and design, data collection, data analysis, manuscript writing, manuscript review

**Misha Ansari:** Protocol writing, data collection, data analysis, manuscript writing.

**Maria Liaqat:** Protocol writing, data collection, data analysis, manuscript writing.