

DIAGNOSTIC ISSUES AND CLINICAL SPECTRUM OF CHILDHOOD DEGENERATIVE BRAIN DISEASES

Tipu Sultan¹, Ashfa Ameer Khan², Muhammad Arshad Khawaja³, Zia ur Rahman¹, Ahsan Waheed Rathore³

¹Department of Paediatric Neurology, The Children Hospital and Institute of Child Health, Lahore, Pakistan

²Department of Radiology, The Children Hospital and Institute of Child Health, Lahore, Pakistan

³Department of Paediatric Medicine, The Children Hospital and Institute of Child Health, Lahore, Pakistan

Correspondence to: Dr. Tipu Sultan, 598-D, Johar Town, Lahore, Pakistan. E-mail: tipusultanmalik@hotmail.com

Date of submission: August 19, 2014, **Date of revision:** October 20, 2014, **Date of acceptance:** November 1, 2014

ABSTRACT

Objectives: To find out the spectrum of clinical presentation and types of neurodegenerative disorders of childhood in tertiary care child neurology centre of Pakistan. To find out the role of brain imaging in the diagnosis of degenerative brain disorders in children. **Methods:** It will be a retrospective, descriptive study conducted at department of paediatric neurology, The Children's Hospital, Institute of child health, Lahore, Pakistan from January 1st, 2004 to December 31, 2013 (10 years). A total of 22,737 patients were admitted in the Paediatric Neurology department in the above said period. Out of them 366 children fulfilled the inclusion criteria. History, clinical examination and relevant investigations were evaluated from the files manually and proformas were filled. **Results:** Male to female ratio was 1.43:1 with 78% incidence of consanguinity. Age range was twenty five months to eighteen years. Metachromatic leukodystrophy was the predominant type (21%) followed by adrenoleukodystrophy (1%) and cerebral atrophy (9.5%) and 3% of each Alexander disease, Hurler's disease, one case each of multiple sclerosis and ataxia telangiectasia. **Conclusion:** Degenerative brain diseases are common entity in paediatric population. Commonest presentation is regression of milestones with variable presentation. General pediatricians must be aware of their clinical presentation look into it when dealing with children having regression of milestones to diagnose them earlier. Because of limited diagnostic modalities, brain imaging has significant value. Facilities for molecular genetics and enzymes should have been available. Regional diagnostic laboratories should have been established and more research is required in this area.

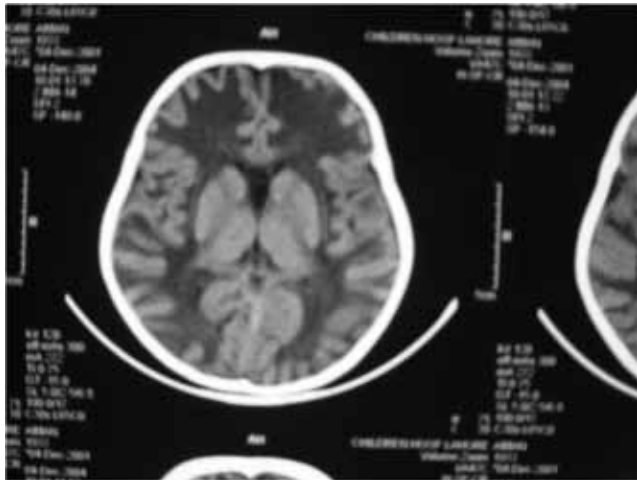
Key Words: Neurodegeneration, Gaucher disease, Metachromatic leukodystrophy, Adrenoleukodystrophy, Alexander disease, Canavan disease.

INTRODUCTION

Degenerative brain diseases (DBD) are chronic, progressive disorders of brain with invariably fatal outcome⁽¹⁾. Majority of these disorders are genetic in nature in which a child starts regressing milestones⁽²⁾. Progressive loss of acquired milestones are the chief symptoms along with seizures, spasticity, feeding difficulties, visual or hearing impairment and regression of intellect⁽³⁾. Neurodegeneration in children is increasingly recognized by general practitioners and pediatricians because of increasing awareness⁽⁴⁾. In the young children, they represent an important cause of progressive neurological disability. They are frequently recognized on MRI, but their identification remains a challenge⁽⁵⁾. Precise diagnosis is important for prognosis, palliative care and possible treatment options. It is also mandatory for family screening and genetic counseling⁽⁶⁾. The diagnostic strategy rests upon clinical clues and MRI patterns, complemented by appropriately selected electrophysiological and laboratory testing. Considerable overlap exists between white and gray matter disease, as neuronal

degeneration will result in myelin loss. An understanding of the pathophysiology and natural disease evolution is necessary for the development of treatment modalities⁽⁷⁾. Majority of DBD require long term palliative care as many have limited therapeutic options, so for the purpose of genetic counseling, correct diagnosis is important⁽⁸⁾. These days brain and rectal biopsies are practically not done and advancement in neuroimaging techniques and molecular genetics has replaced them⁽⁹⁾. Pakistan has high birth rate and consanguinity is one of the major reasons for huge burden of inherited neurometabolic disorders⁽¹⁰⁾. The disease is more common than had been previously recognized due to phenotypic variability and wide spectrum of presentation. Because of poor diagnostic facilities, this condition was not well understood⁽¹¹⁾. We have limited community based local data available to quantify the burden of disease⁽¹²⁾. Only local data available is from tertiary care hospital⁽¹³⁾. This study was designed to find out the different types of degenerative brain disorders prevalent in our community. Their modes of presentation will be evaluated and role of neuroimaging will be assessed.

FIGURE –I



MRI BRAIN
Bilateral Hypointense Signals T-1 images
METACHROMATIC LEUKODYSTROPHY

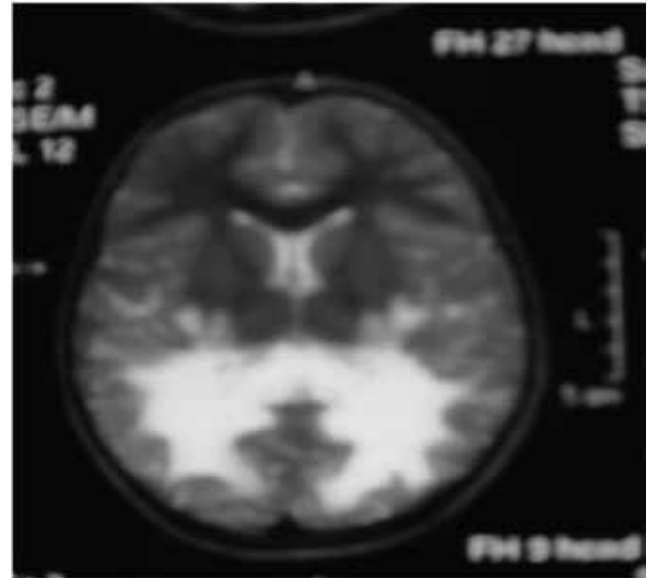
PATIENTS AND METHODS

It is a retrospective, descriptive case study conducted at the department of paediatric neurology, Children's Hospital and Institute of child health, Lahore, Pakistan. Files of all children admitted with regression of milestones on history were enrolled in the study.

Inclusion Criteria was: History of regression of acquired milestones and age between two years to 18 years. Exclusion criteria was: All children having a history suggestive of cerebral palsy, neuromuscular disorders, hypoxic ischemic encephalopathy, central nervous system infections (meningitis, encephalitis, cerebral malaria, brain abscess), congenital infections like TORCH infections, space occupying lesion of brain or spine, progressive hydrocephalus or other problems leading to static neurological deficit were excluded. All patients presenting to paediatric neurology department fulfilling the above cited criteria were included in study. All files of admitted patients were evaluated and study performance's were filled manually. Following investigations were done during their stay in the ward and entered in the performance's includes computed tomography (CT scan) of brain, magnetic resonance imaging (MRI) [T1, T2 weighted and flairs images, in axial, sagittal, coronal sections of brain and spinal cord where necessary. Electrophysiological studies including, nerve conduction velocity and electromyography (NCV/EMG), electroencephalography (EEG), audiometry, CSF studies (proteins, sugar, anti measles antibodies), fundus examination for optic atrophy, pigmentation, slit lamp examination for Keisher-Fliesher ring, bone marrow examination (where needed)

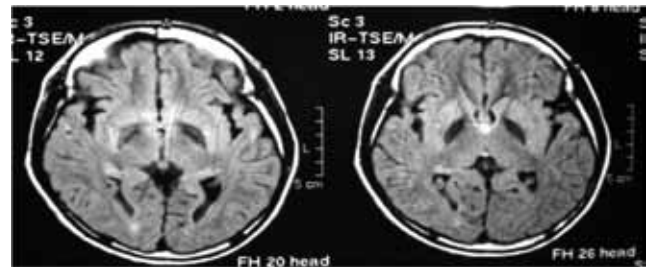
and urinary copper estimation (where needed) were done. This is an observational study, hence no statistical test can be applied.

FIGURE-II



MRI BRAIN
Bilateral Posterior Hyperintense Signals
ADRENOLEUKODYSTROPHY

FIGURE-III



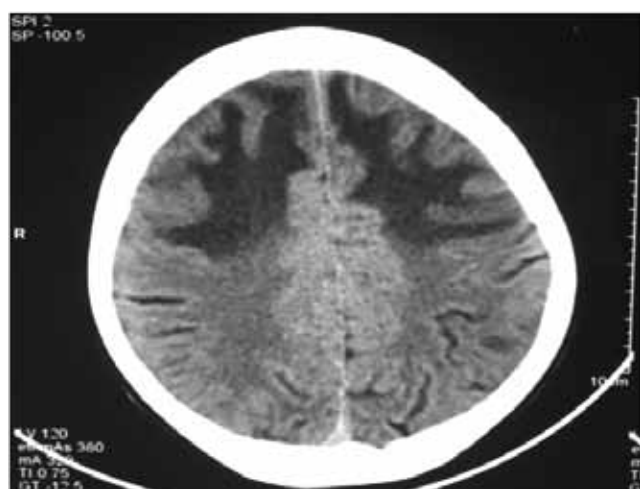
Flair Axial Images
HELLERVORDEN SPATZ DISEASE

RESULTS

During the study period, 22737 patients were admitted in the unit. Initially 678 files were selected with the possible diagnosis of DBD, in whom children were presented with regression of milestones. After the detail scrutiny of all the files, 366 (1.6%) children qualified the inclusion criteria. There were 215 (59%) males and 151 (41%) females with male to female ratio of 1.43:1. The age range was two years to 18 years. Mean age of onset of symptoms was 3.8 years while mean age at diagnosis was 4.7 years. Consanguinity among parents was noted in 270 (74%) cases and history of affected siblings was noted in 117 (32%) cases.

Evaluation of different age groups revealed that 96 children (26%) presented with age less than 5 years, 172 children (47%) with age between 5 to 10 years while 98 children (27%) were of age above 10 years. Spasticity of varying degree was seen in 252 (69%) patients, while ataxia was seen in 121(33%) cases. Children presented with speech difficulties were 117 (32%), with hearing problem 95 (26%), with seizures 256 (70%), with visual problems 51 (14%) and 62(17%) patients presented with dystonia. There were 7% (26) patients who had epileptic discharges with myoclonic jerks on EEG, 70(19%) patients had findings suggestive of generalized epileptiform activity and 33 children (9%) had demyelinating neuropathy on NCVs.

FIGURE-IV

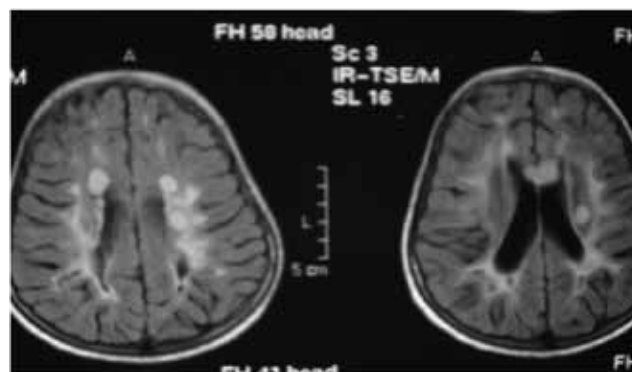


CT BRAIN
Bilateral Hypodence Lesions
Involving Frontal Horns White Matter
ALEXANDER'S DISEASE

Cerebrospinal fluid biochemistry showed elevated proteins (50-100 mg/dl) in 175(48%) cases. Metachromatic leukodystrophy (figure-I) was the predominant type, seen in 79(21%) cases, followed by 72(19%) children with adrenoleukodystrophy (figure-II). Brain atrophy (figure-VI) was one of the common finding seen in our data with 31 (8.5%) children with cerebral atrophy, 12 (3.3%) children with cerebellar atrophy and 19 (5.2%) children with combined cerebral and cerebellar atrophy. It makes the brain atrophy 3rd largest group (62 children / 17%) after the MLD and ALD. There were 22 (6%) patients with the diagnosis of sub acute sclerosing panencephalitis (SSPE), 12 children (3.3%) diagnosed as Wilson Disease, 9 (2.5%) were diagnosed as Fredrich ataxia. There were 23 cases (6.3%) of Hellervordenspatz disease (figure-III), 11 (3%) cases of Alexander disease (figure-IV), 10 patients (2.7%) were diagnosed as canavans disease (figure-VII) and 5 cases(1.4%) of multiple sclerosis(figure-V) and 13(3.5%) cases of ataxia telangiectasia. Lipidosis was the diagnosis in 4 children (1.1%)

while Gauchers disease type III was present in 2 cases (0.5%). We were unable to make a definitive diagnosis in 21 (5.7%) children.

FIGURE-V



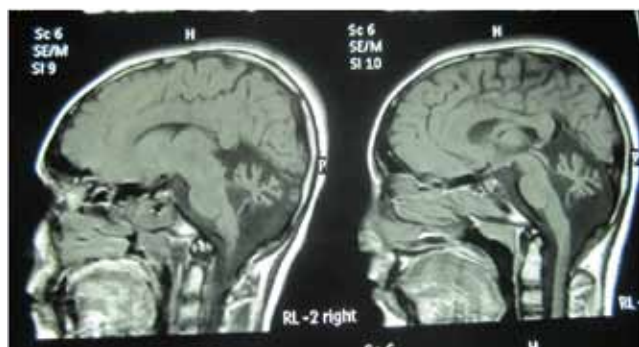
MRI BRAIN
(Flair Axial Section)
Bilateral Hyperintence Lesions
MULTIPLE SCLEROSIS

DISCUSSION

Childhood neurological disorders are important and frequent problems particularly in developing countries, led to significant financial burden for the family health care system and community. Underlying disorders vary significantly in incidence and severity compared to developed countries. The outcome will also differ based on early diagnosis, prompt effective therapy, rehabilitation and nursing care for the survivors. Degenerative brain diseases are growing group of chronic neurological disorders owing to advancement in MRI and in the field of molecular genetics over the recent years⁽¹⁴⁾. DBD are caused by mutations in single genes and follow mendelian genetics. Currently, genes underlying mendelian traits are being discovered rapidly compared with those for complex traits⁽¹⁵⁾. Therefore, we expect the number of identifiable degenerative brain diseases to increase in the coming years⁽¹⁶⁾. There are few studies done in Pakistan to look into the presentation and diagnostic challenges in DBD with small samples. If we compare the previous local data of DBD, one of the study done in Islamabad concluded that it is really difficult to diagnose DBD with limited diagnostic facilities. In that study only, one fourth children had been diagnosed while majority of children remained under the category of unclassified. Leukodystrophies were the commonest diagnosis like in our study. Consanguinity was present in majority of parents (90%) and it is slightly more common as compared to our sample, may be due to different geographical location. Thirty eight percent patients had one or more sibs affected with similar neurological disorders and it is more or less the same finding as in our data⁽¹⁷⁾. MRI of brain is the most important test in a patient suspected of having a DBD, which

is now widely available in the country. Correlation between the MRI brain results with clinical findings may vary, still it is believed to be one of the best tool for clinicians ⁽¹⁸⁾.

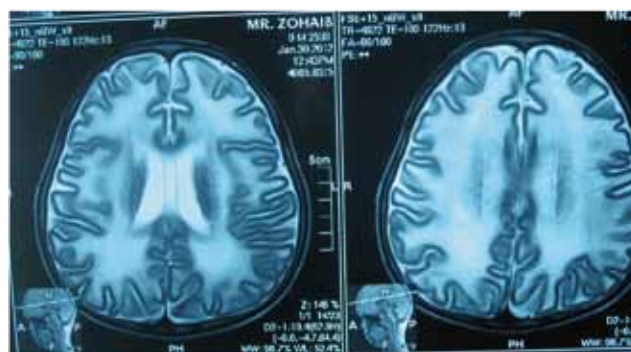
Figure-VI



MRI Brain shows Marked Cerebellar Atrophy

Certain patterns of MRI and localizations of lesions is crucial in differentiating the metabolic/degenerative diseases from inflammatory lesions ⁽¹⁹⁾. Evoked potentials and nerve conduction velocities are helpful in differentiating degenerative brain diseases from demyelinating disorders ⁽²⁰⁾. Patients with X-ALD show normal nerve conduction velocities, while patients with metachromatic or globoid cell leukodystrophy commonly display abnormalities. In Krabbe disease, the severity of abnormalities in NCS appears to correlate with clinical severity ⁽²¹⁾. In general, NCS more frequently reveals abnormalities in symptomatic patients than evoked responses. In our study population, EMG/NCS revealed abnormal findings in 47 children, and help us in labeling them as specific neurological disorder. Severity of disease revealed in MRI correlates with that seen on NCS and clinical data. So NCS along with brain MRI appear to be the most sensitive tool to help in the evaluation of severity and classification of globoid cell leukodystrophy ⁽²²⁾. Brainstem auditory evoked responses (BAER) are usually normal in X-ALD during first decade of life but, later become abnormal when demyelination extends to the brainstem and spinal cord. There are 27 children who show abnormal findings on the Visual-evoked potentials (VEP). (VEP) in X-ALD become abnormal once there are extensive demyelinating lesions in the occipital white matter, somatosensory-evoked potentials and motor-evoked responses even later in the course of the disease ⁽²³⁾. Children may have an abnormal neurophysiological findings while have normal MRI pattern and hence this investigation is more sensitive than brain imaging to identify the abnormalities. Usually BAER are first to be abnormal, then somatosensory-evoked potential of the lower limbs and then motor-evoked responses to lower limbs ⁽²⁴⁾.

Figure- VII



MRI Brain shows marked demyelination in Canavans leukodystrophy

In another study done in pediatric department of postgraduate medical institute, Lahore, it is concluded that 6.7% children (408/6089) were admitted with neurological disorders with male predominance (61.7%). These results were comparable with the current study in many respects though the objectives were different from our study. Degenerative brain disorders were one of the commonest subgroup among the neurological disorders with highest case fatality rates (30.4%). Childhood neurological disorders in developing countries cause significant morbidity and end up as high case fatality. Congenital and perinatal problems, infections of the brain, tumors of brain and epilepsy constitute major burden. Simple measures like mass immunizations, good antenatal and postnatal care and improved rehabilitation services can reduce the burden of neurological diseases and outcome ⁽²⁵⁾. Laboratory tests should have been ordered after thorough evaluation of clinical and imaging findings as they are frequently of low yield and cause high costs ⁽²⁶⁾. The utility of individual tests is established through the findings on a focused clinical examination and suspicion arising from an analysis of the imaging pattern ⁽²⁷⁾. A number of tests that may be useful to do relatively early in the diagnostic process include those listed in the table-I. Previous published local data suggests the huge burden of disease but due to lack of diagnostic facilities in developing countries, limited progress has been done. Now with the access of neurophysiology, neuroimaging and some of the relevant enzymatic studies, DBD can be diagnosed and differentiated from other conditions. Lack of awareness at primary care level and limited diagnostic facilities may led to either delayed diagnosis or wrong diagnosis ⁽²⁸⁾. Parents who had one or more affected children were swifter to recognize abnormality in subsequent children. EEG was suggestive of non-specific seizure discharges in 21 (31%) patients. Nerve conduction velocity demonstrated marked decrease of nerve conduction velocities, both motor and sensory, suggestive of demyelinating neuropathy in 19

(29%). MLD was the predominant type of leukodystrophy seen in our study with 14 (21%) children, the other rare types were also seen like Alexander disease 2 (3%). Comparable results were described another local data by Matloob Azam⁽¹⁷⁾. DBD are one of the major problems in child neurology with significant financial burden on the families and health care system due to delay in diagnosis. Brain imaging (CT brain: 34 cases and MRI brain:5 cases) was taken as tool to evaluate 39 children with progressive neurological disorders. Results showed abnormal findings in 33 children (27 cases) in CT brain and 3 cases of MR brain. Radiological interpretation reveals demyelination, cortical atrophy/ cerebellar atrophy, calcification, hyper-density areas or hypodensity areas of cerebrum. It was concluded in the study that MRI or CT scan brain should be part of evaluation of a child in some kind of neurodegenerative disorder is suspected⁽²⁹⁾. Neuro degenerative disorders are progressive disorders with significant morbidity and mortality with adverse socioeconomic impact on the family. They require thorough work up once they are suspected. Multidisciplinary approach and genetic counseling must be offered to every confirmed case. Health education regarding the immunization can decrease high incidence of SSPE⁽³⁰⁾. Over the past three decades, Paediatric Neurology has made lot of progress. It is a dynamic field and offering a new ray of hope to most of the neurological patients⁽³¹⁾. Despite the fact that there is a big number who has this group of huge number of children, there is no facility for enzyme studies all our Pakistan. Simple measure like treatment of spasticity, control of fits, preventing bed sores, regular physiotherapy, providing them mobility aids, treatment of infections, care of nutrition and anemia, audiological and ophthalmologic assistance may improve their quality of life⁽³²⁾.

CONCLUSION

DBD are common neurological disorders in the children of developing countries. Their clinical presentation is variable and brain imaging is very helpful in diagnosis. Facilities for molecular genetics and enzymes should be available in tertiary care paediatric hospitals and specialized regional centers should be established.

Table 1: Spectrum of Investigations (n=366)

S.No	Name of Investigation	Number	Percentage
01	MRI Brain	344	94%
02	CT Brain	336	92%
03	Electroencephalogram	366	100%
04	NCS/EMG	205	56%
05	Audiometry	70	19%
06	CSF Examination	318	87%
07	Fundoscopy / Slit lamp examination	238	65%
08	Visual Evoked Potentials	11	03%
09	Bone Marrow examination	14	04%

Table 2: Spectrum of Diagnosis (n=366)

S.No	Name of Disease	Number	Percentage
01	Metachromatic leukodystrophy (MLD)	79	21%
02	Adrenoleukodystrophy (ALD)	72	19.7%
03	Cerebral atrophy	31	8.5%
04	Haller Worden Spatz Disease	23	6.3 %
05	Sub acutesclerosingpanencephalitis (SSPE)	22	6 %
06	Familial spastic paraplegia	21	5.7%
07	Cerebral and Cerebeller atrophy	19	5.2 %
08	Ataxia telangiectasia	13	3.5 %
09	Wilson Disease	12	3.3 %
10	Cerebeller atrophy	12	3.3 %
11	Alexander Disease	11	3 %
12	Canavans disease	10	2.7 %
13	Friedreich ataxia	9	2.5%
14	Multiple Sclerosis	5	1.4 %
15	Lipidosis	4	1.1 %
16	Gaucher Disease Type III	2	0.5 %
17	Unclassified	21	5.7 %
18	Total	366	

REFERENCES

1. Fenichel GM. Psychomotor retardation and regression In: Clinical paediatric Paediatric Neurology. 7th Edition 2013. WB Saunders USA. 117-47.
2. Azam M. Degenerative brain disease and neuroimaging in children. J Coll Physicians Surg Pak 1999;9 (3): 127-31.
3. Perey AK. Inherited neurodegenerative diseases. The evolution of our thinking. J. Child Neurol 1999; 12:256-62.
4. Afzal M, Shahid M. Children presenting with seizures-A hospital based study. J Coll Physicians Surg Pak 1999;9 (3):132-5.
5. Alan Jackson. Neurodegenerative and white matter disease. In: James E. Gillespie, Alan Jackson (edi). MRI and CT of the brain. New York: Arnold publishers 2000;241-165.
6. Kaye EM, Update on genetic disorders affecting white matter. PediatrNeurol 2001 Jan; 24(1):11-24.
7. Arbout LT, Sliver K, Hetatman P, Treacy EP, Variable onset of metachromatic leukodystrophy in a Vietnamese family. PediatrNeurol 2000 Aug; 23(2):173-6.
8. Krivit W, Aubourg P, Shapiro E, Peters C: Bone marrow transplantation for globoid cell leukodystrophy, adrenoleukodystrophy, metachromatic leukodystrophy and Hurler syndrome. Cur Opin Hematol 1999 Nov 6(6): 377-82.
9. Berger J, Moser HW, Forss-Petter S: Degenerative brain diseases: Recent developments in genetics, molecular biology, pathogenesis and treatment. Curr Opin Neurol 2001; 14:305.
10. Ahmad I, Yasin F, Iqbal K. Diagnosis of storage diseases in children by bone marrow examination. Pakistan Ped J 1995; 19 (1):15-7.
11. Sultan T, Zuberi S, McWilliam R. Paediatric Neurology

- training- A developing country perspective. *J Coll Physicians Surg Pak* 2006;16(7):282.
12. Schiffmann R, van der Knaap MS. an MRI-based approach to the diagnosis of white matter disorders. *Paediatric Neurology*2009; 72(8),750-59.
 13. Steenweg ME, Vanderver A, Blaser S. Magnetic resonance imaging pattern recognition in hypomyelinating disorders. *Brain*2010; 133(10),2971-82.
 14. Lin J, Faria EC, Da Rocha AJ. Leukoencephalopathy with brainstem and spinal cord involvement and normal lactate: a new mutation in the DARS2 gene. *J. Child Neurol* 2010;25(11),1425-28.
 15. Jose RA, Tulio BF, Carlos MMA Jr. Lactate detection by MRS in mitochondrial encephalopathy: optimization of technical parameters. *J. Neuroimaging* 2008; 18(1),1-8.
 16. Loes DJ, Fatemi A, Melhem ER. Analysis of MRI patterns aids prediction of progression in X-linked adrenoleukodystrophy. *Paediatric Neurology* 2003; 61(3),369-74.
 17. Azam M. Neurodegenerative diseases of infancy and childhood. *Pak J Pathol* 1996;7(3):111-8.
 18. Provenzale JM, Peddi S, Kurtzberg J, Poe MD, Mukundan S, Escolar M. Correlation of neurodevelopmental features and MRI findings in infantile Krabbe's disease. *Am. J. Roentgenol.*2009; 192(1),59-65.
 19. Eichler F, Grodd W, Grant E et al. Metachromatic leukodystrophy: a scoring system for brain MR imaging observations. *Am. J. Neuroradiol.*2009; 30(10),1893-97.
 20. Husain AM, Altuwajiri M, Aldosari M. Krabbe disease: neurophysiologic studies and MRI correlations. *Paediatric Neurology* 2004; 63(4),617-20.
 21. van der Knaap MS, Pronk JC, Scheper GC. Vanishing white matter disease. *Lancet Neurol.*2006; 5(5), 413-23.
 22. Siddiqi ZA, Sanders DB, Massey JM. Peripheral neuropathy in Krabbe disease: electrodiagnostic findings. *Paediatric Neurology* 2006; 67(2),263-67.
 23. Moser HW, Raymond GV, Dubey P. Adrenoleukodystrophy: new approaches to a neurodegenerative disease. *JAMA*2005;294(24),3131-34.
 24. Dubey P, Raymond GV, Moser AB, Kharkar S, Bezman L, Moser HW. Adrenal insufficiency in asymptomatic adrenoleukodystrophy patients identified by very long-chain fatty acid screening. *J. Pediatr.*2005 146(4),528-32.
 25. Zaheer A, Rashid A, Chishty AL. Neurological disease spectrum and associated factors for morbidity and mortality among admitted children. *Pak Paed J* 2009;33(1):24-9.
 26. Laureti S, Casucci G, Santeusano F, Angeletti G, Aubourg P, Brunetti P. X-linked adrenoleukodystrophy is a frequent cause of idiopathic Addison's disease in young adult male patients. *J. Clin. Endocrinol. Metab.* 1996;81(2),470-74.
 27. Klick JC, Hauer J. Pediatric palliative care. *Curr. Probl. Pediatr. Adolesc. Health Care* 2010; 40(6), 120-51.
 28. Hauer JM, Wical BS, Charnas L. Gabapentin successfully manages chronic unexplained irritability in children with severe neurologic impairment. *Pediatrics* 2007;119(2),519-22.
 29. Azam M. Degenerative brain diseases and neuroimaging in children. *J Coll Physicians Surg Pak* 1999;9(3):127-31.
 30. Azam M, Bhatti N, Krishin J, Hazir T. Subacute sclerosing panencephalitis. *J Pakistan Inst Med Sci* 2002;13(1): 618-22.
 31. Moser HW, Raymond GV, Lu SE et al. Follow-up of 89 asymptomatic patients with adrenoleukodystrophy treated with Lorenzo's oil. *Arch. Neurol.* 2005; 62(7),1073-80.
 32. Shafqat S, Wasay M. Paediatric Neurology in the 21st Century: Contemporary state of diagnostics and therapeutics. *J Pak Med Assoc* 2004; 54 (5): 271-6.

Conflict of interest: Author declares no conflict of interest.

Funding disclosure: Nil

Author's contribution:

Dr. Tipu Sultan: Study concept and design, protocol writing, data collection, data analysis, manuscript writing, manuscript review

Dr. Ashfa Ameer Khan: Study concept and design, data collection, data analysis, manuscript writing, manuscript review

Dr. Muhammad Arshad Khawaja: data collection, data analysis, manuscript writing, manuscript review

Dr. Ziaur Rahman: manuscript writing, manuscript review

Dr. Ahsan waheed Rathore: data analysis, manuscript writing, manuscript review