

ENDOVASCULAR TREATMENT OF SPONTANEOUS INDIRECT HIGH FLOW CAROTID CAVERNOUS FISTULA WITH A COVERED STENT.

Dr.Qasim Bashir¹, Dr.Hina Nabi Ahmed²

¹ Department of Interventional Neurology, Bahria Town Hospital, Lahore, Pakistan.

² Department of Anesthesia, Bahria Town Hospital, Lahore, Pakistan.

Correspondence to: Dr.Qasim Bashir, Department of Interventional Neurology, Bahria Town Hospital, Lahore, Pakistan. Email: qbashir@hotmail.com

Date of submission: July 5, 2014, **Date of revision:** August 25, 2014, **Date of acceptance:** September 12, 2014

ABSTRACT

Objective: The treatment of symptomatic carotid-cavernous fistulas [CCF] has been historically treated in the developed world through the endovascular route. We report our first case of using a covered stent in a patient with spontaneous CCF. **Method:** Single patient with spontaneous indirect high flow CCF treated with a covered stent. We present retrospective analysis of technical success, initial and 6-month follow-up angiography and clinical outcome. **Result:** The stent was successfully navigated and deployed covering the CCF orifice. Immediate post stent deployment angiography showed marked reduction in flow and complete occlusion at 6-months. Clinically, patient showed near-complete recovery at 6 months. **Conclusion:** With proper neuroendovascular training and experience, use of a covered stent is cost effective and feasible for the treatment of CCFs in under developed countries.

Key Words: Carotid-cavernous fistula, spontaneous, endovascular treatment, Covered stents.

INTRODUCTION

Abnormal communication between the carotid arterial system and cavernous sinus results in Carotid Cavernous Fistula [CCF]. Iatrogenic damage [trans-sphenoidal surgery, glycerol rhizotomy etc] as well as blunt and penetrating head trauma may lead to direct CCF⁽¹⁻²⁾. CCFs not associated with history of trauma are regarded as spontaneous. Conditions that weaken the Internal Carotid Artery [ICA] wall can lead to spontaneous CCF. Predisposing conditions include rupture of carotid cavernous aneurysm, atherosclerosis, connective tissue disorders like Ehlers-Danlos syndrome, fibromuscular dysplasia and pseudoxanthoma elasticum⁽³⁻⁷⁾. Treatment modalities include conservative approach i.e. manual compression therapy, surgical management [carotid ligation], stereotactic radiosurgery and endovascular management encompassing either or combination of transarterial and transvenous approaches. Endovascular transarterial technique employing reconstructive approach with a covered stent has shown impressive results. This technique reduces the procedure time and cost by covering the fistula ostium⁽⁸⁻¹¹⁾. The purpose of our study was to present our preliminary experience and feasibility of using a covered stent for CCF treatment.

TECHNIQUE

A 35-year-old man sought medical attention with a few weeks history of gradually progressive conjunctiva and

episcleral vessel venous congestion, visual blurring and exophthalmos. His detailed ophthalmologic examination had earlier shown elevated intraocular pressure. Prior to the procedure, patient had received coated Aspirin [75mg/d] and Clopidogrel [75mg/d] for 5 consecutive days. The procedure was performed under general anesthesia. After a 6-F guide catheter was positioned in the distal right carotid artery, the initial diagnostic angiography showed an indirect right CCF⁽¹²⁾. [Barrow's Classification – Type D]. The arterial supply to the CCF was from the capsular branches of the right cavernous ICA [Fig 1] and a few tiny feeders from the right External Carotid Artery [ECA] [Fig 2]. Its venous drainage was into the cavernous sinus and superior ophthalmic vein. Based on the angiographic findings a vessel reconstructive approach using a covered stent was planned. Abbott Vascular Jostent Grafmaster is a low profile stent system constructed using a sandwich technique with an ultra-thin expandable Polytetrafluoroethylene (PTFE) placed between the two stainless steel Jostent stents. The patient was systemically heparinized and serial ACTs were obtained at regular intervals. A 0.014 mm BMW microwire was navigated into a distal branch of right middle cerebral artery. Under road map guidance, a Jostent Grafmaster 3.5 mm x 16mm was advanced and the orifice of the fistula was bridged. Immediate post stent angiography confirmed accurate stent placement but stent endoleak was noticed. The stent was post dilated to stop or further reduce the endoleak using UltraSoft

5.0x20x153cm angioplasty balloon. Then, Microvention Headway 17 micro catheter was advanced over BMW 0.014mm microwire and its tip positioned into the right internal maxillary arterial fistulous feeder branch to the right CCF. The branch was intentionally sacrificed using 0.5cc of approximately 33% diluted n-butyl cyanoacrylate [n-BCA] glue. Post procedure angiography demonstrated complete obliteration of the right ECA branch arterial feeders to the right CCF and mild stent endoleak with angiographically-reduced flow in the Right CCF [Fig 3]. The patient recovered from anesthesia uneventfully and reported improvement with his vision and reduction in exophthalmos. He was instructed to continue dual antiplatelet therapy for 6 months to avoid thrombosis and in-stent stenosis. Patient's six-month follow-up angiography showed complete obliteration of the right CCF [Fig 4]. The clinical follow-up assessment was graded as near full recovery with improving residual mild chemosis and exophthalmos.

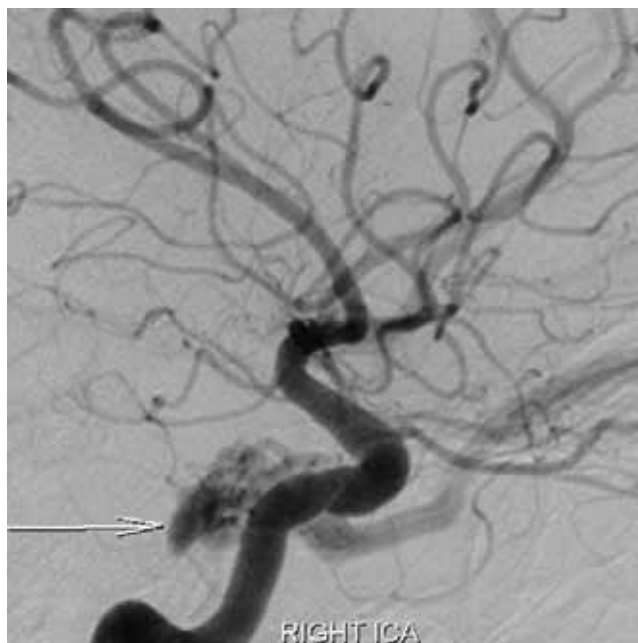


Fig 1: Selective Right ICA angiography [Oblique view] showing indirect Right CCF.

DISCUSSION

The first therapeutic modality for CCFs currently is the Endovascular embolization because it is associated with high occlusion and low complication rates. The endovascular therapeutic modalities for CCFs involve the use of different embolic materials including detachable balloons, silk, coils, n-butyl cyanoacrylate (n-BCA), covered stents, and Onyx. In our experience, we found the use of a covered stent as a feasible therapeutic option for indirect CCF. The final angiogram showed

complete occlusion of the fistula without recanalization and parent artery patency without in-stent stenosis. Indirect CCFs are also called dural fistulas and harbor low flow rate. Such fistulas can be approached via transvenous and transarterial routes. In the transvenous approach the abnormal cavernous sinus is superselectively catheterized to occlude the fistula without compromising the venous drainage (1,3, 13). The technical challenge to the transvenous approach includes venous perforation. Depending on venous route chosen can be fatal if the brainstem is involved. The transarterial technique involves catheterization of the ECA arterial feeders followed by satisfactory occlusion using liquid embolic agents [n-BCA, EVOH, Onyx]. Other therapeutic modalities include detachable balloon [DB] occlusion of the CCF (14, 17). Residual or recurrent CCF and pseudoaneurysm formation is major complication associated with DBs. Coil embolization is another alternative approach to occlude these fistulas. It was entertained in our case but was not considered feasible because of high cost and non-availability of surgical expertise to acquire direct supra orbital access via the superior ophthalmic vein. Covered stents have been used in a vast array of cerebrovascular disorders including aneurysms, dissection, pseudoaneurysm and CCFs (8-11, 18-21). The technically important and challenging factor is the complete closure of the fistula orifice. The drawbacks include CCF recurrence and endoleak that does not occur if the orifice is completely closed. In our case, the covered stent could be delivered safely.

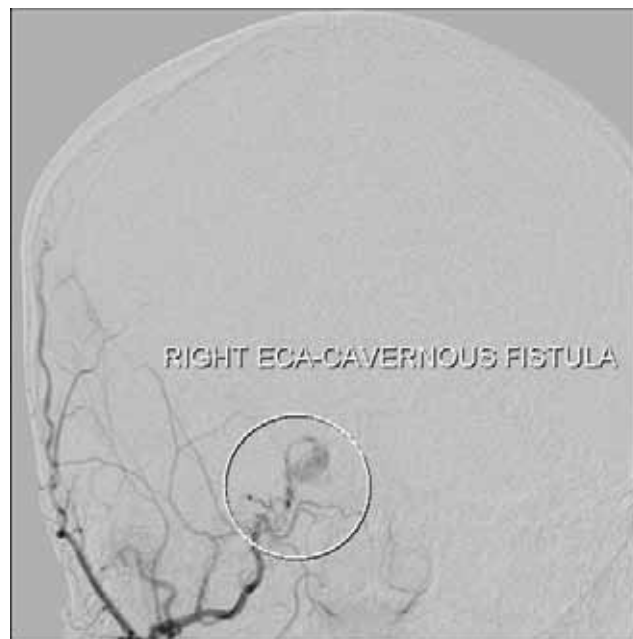

Fig 2: Selective Right ECA Angiography [Anteroposterior view] showing an arterial feeder to the Right CCF.

As such, stents are not readily available in Pakistan. Hence, we had to rely on the slightly smaller diameter stent followed by post deployment larger diameter balloon angioplasty. Post angioplasty, the degree of endoleak improved. Even though the patient symptoms were improving but he was brought back for a second attempt to deliver a larger diameter stent at four months but the stent navigation through the previously deployed stent was technically challenging and the procedure was aborted.

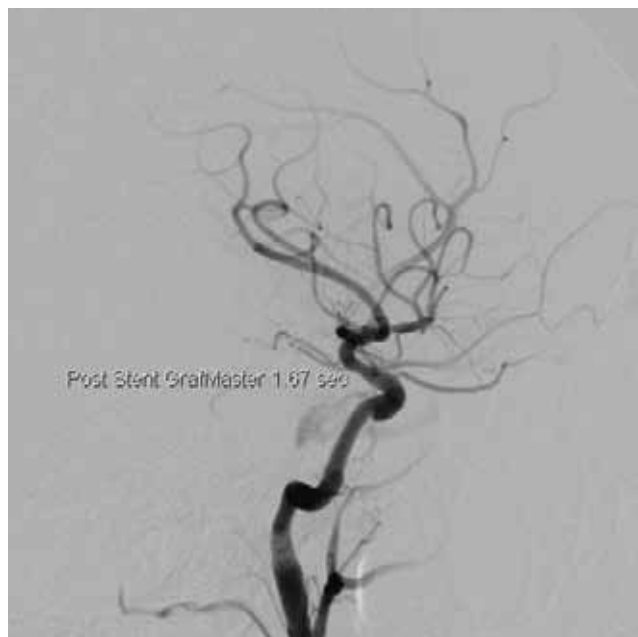


Fig 3: Immediate post stenting angiography showing markedly reduced flow secondary to stent endoleak into the Right CCF.

He was instructed to switch to a single antiplatelet agent. At Six months follow-up, angiography showed complete occlusion of the CCF. Neuroendovascular therapy in a country like Pakistan with fragile economy brings additional challenges such as a scarcity of neuro-interventional disposables due to problems with the import of these expensive materials and the necessity to succeed in completely embolizing a given CCF, aneurysm etc. to justify the costs involved. Training of specialists remains a difficult task due to the scarcity of both materials and physician tendency to start self-learning these high risk procedures without professional oversight. In conclusion, our initial experience of using a covered stent to treat CCF in Pakistan indicates procedural feasibility, increased occlusion and anatomic cure rates, elimination of the mass effect and reduced cost of treating such fistulas without compromising the parent vessel. Long term clinical follow-up studies are needed.

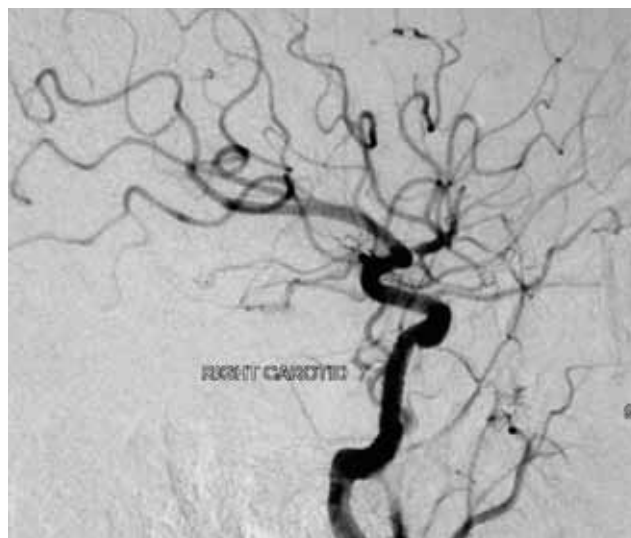

Fig 4: Six-Month follow-up angiography showing complete obliteration of the right CCF.

REFERENCES

1. Tjoumakaris SI, Jabbour PM, Rosenwasser RH. Neuroendovascular management of carotid cavernous fistulae. *Neurosurg Clin N Am* 2009; 20: 447-452.
2. Connors JJ, Wojak JC. *Interventional Neuroradiology: Strategies and Practical Techniques*. Philadelphia: WB Saunders Co., 1999: 215-226.
3. Gemmete JJ, Ansari SA, Gandhi DM. Endovascular techniques for treatment of carotid-cavernous fistula. *J Neuroophthalmol* 2009; 29: 62-71.
4. Tomsick TA. Type A (direct) CCF: etiology, prevalence, and natural history. In: Tomsick TA, editor. *Carotid cavernous sinus fistula*. Cincinnati: Digital Education Publishing, 1997: 35-38.
5. Wanke I, Doerfler A, Stolke D, Forsting M. Carotid cavernous fistula due to a ruptured intracavernous aneurysm of the internal carotid artery: treatment with selective endovascular occlusion of the aneurysm. *J Neurol Neurosurg Psychiatry* 2001; 71: 784-787.
6. Germain DP, Herrera-Guzman Y. Vascular Ehlers-Danlos syndrome. *Ann Genet* 2004; 47: 1-9.
7. Debrun GM. Angiographic workup of a carotid cavernous sinus fistula (CCF) or what information does the interventionalist need for treatment? *Surg Neurol* 1995; 44: 75-79.
8. Felber S, Henkes H, Weber W, et al. Treatment of extra cranial and intracranial aneurysms and arteriovenous fistulae using stent grafts. *Neurosurgery*. 2004; 55: 631-638.
9. Gomez F, Escobar W, Gomez AM, et al. Treatment of carotid cavernous fistulas using covered stents: midterm results in seven patients. *Am J Neuroradiol*.

- 2007;28: 1762-1768.
10. Wang C, Xie X, You C, et al. Placement of covered stents for the treatment of direct carotid cavernous fistulas. *Am J Neuroradiol.* 2009; 30: 1342-1346.
 11. Wang W, Li YD, Li MH, et al. Endovascular treatment of posttraumatic direct carotid-cavernous fistulas: a Single-center experience. *J Clin Neurosci.* 2010; 18: 24-28.
 12. Barrow DL, Spector RH, Braun IF, et al. – Classification and treatment of spontaneous carotid cavernous sinus fistulas. *J Neurosurg* 1985; 62:248-256.
 13. Ringer AJ, Salud L, Tomsick TA. Carotid cavernous fistulas: anatomy, classification, and treatment. *Neurosurg ClinN Am* 2005; 16: 279-295
 14. Higashida RT, Halbach VV, Tsai FY, et al. Interventional neurovascular treatment of traumatic carotid and vertebral lesion: results in 234 patients. *Am J Roentgenol.* 1989; 153: 577-582.
 15. Luo CB, Teng MM, Yen D H, et al. Endovascular embolization of recurrent traumatic carotid-cavernous fistulas managed previously with detachable balloons. *J Trauma.* 2004; 56: 1214-1220.
 16. Gupta AK, Purkayastha S, Krishnamoorthy T, et al. Endovascular treatment of direct carotid cavernous fistulae: a pictorial review. *Neuroradiology.* 2006; 48: 831-839.
 17. Debrun G, Lacour P, Vinuela F, et al. Treatment of 54 traumatic carotid cavernous fistulas. *J Neurosurg.* 1981; 55: 678-692.
 18. Li MH, Li YD, Gao BL, et al. A new covered stent designed for intracranial vasculature: application in the management of pseudoaneurysms of the cranial internal carotid artery. *Am J Neuroradiol.* 2007; 28: 1579-1585.
 19. Li MH, Li YD, Tan HQ, et al. Treatment of distal internal carotid artery aneurysm with the Willis covered stent: a prospective pilot study. *Radiology.* 2009; 253:470-477.
 20. Li YD, Li MH, Gao BL, et al. Endovascular treatment of recurrent intracranial aneurysms with re-coiling or covered stents. *J Neurol Neurosurg Psychiatry.* 2010; 81:74-79.
 21. Li MH, Leng B, Li YD, et al. Comparative study of covered stent with coil embolization in the treatment of cranial internal carotid artery aneurysm: a nonrandomized prospective trial. *Eur Radiol.* 2010; 20: 2732-2739.

Conflict of interest: Author declares no conflict of interest.

Funding disclosure: Nil

Author's contribution:

Dr. Qasim Bashir: Study concept and design, protocol writing, data collection, data analysis, manuscript writing, manuscript review

Dr. Hina Nabi Ahmed: Data collection, data analysis, manuscript writing, manuscript review