

FROM TIP TO TPA

Shaista A Siddiqi, Syed Habibullah Kamran, Abubaker A Almadni.

Department of Neurology, Rashid Hospital, Dubai, UAE.

Correspondence to: Shaista A Siddiqi E-mail: ghaniasiddiqi@yahoo.com *Department of Neurology, Rashid Hospital, Dubai, UAE*
Date of Submission: September 01, 2015 **Date of Revision:** October 28, 2015, **Date of Acceptance:** November 10, 2015

ABSTRACT

We present the case of a 50 year old lady who presented with sudden onset altered sensorium, anarthria, right hemianopia, ophthalmoplegia, quadriparesis and abnormal posturing of upper limbs for 4 hours. The NIHSS score was 31. The CT brain showed early ischemic changes in left posterior cerebral artery territory. The CT cerebral angiogram showed occlusion of the tip of basilar artery. Intravenous thrombolysis with rtPA resulted in remarkable recovery and NIHSS improved to 3 within 6 hours. In view of expected severe disability associated with tip of basilar artery syndrome, intravenous thrombolysis can be rewarding even in patients with high NIHSS.

INTRODUCTION

Posterior circulation strokes account for 20% of large artery ischemic strokes, with a reported mortality rate of ~80 % in basilar artery (BA) strokes. The literature on BA occlusion shows a significantly lower risk of poor outcome after intravenous (iv) or intra-arterial thrombolysis as compared to anti-thrombotic agents. Intravenous thrombolysis (recombinant tissue plasminogen activator, rtPA) in acute ischemic stroke when given righteously leads to good functional recovery.

Case summary

This is a case of a 50 years old lady who presented to us with sudden onset altered sensorium, anarthria, right hemianopia, ophthalmoparesis, quadriparesis and abnormal posturing of upper limbs within four hours of onset of symptoms. The collective NIHSS was 31 with a modified Rankin scale (mRS) of 5. The 12-lead ECG showed atrial fibrillation with ischemic changes. Later, the trans-thoracic echocardiogram showed rheumatic heart disease with dilated atria and right ventricle, global hypokinesia with severe left ventricular systolic dysfunction; and severe mitral stenosis with mitral valve area of 0.9cm². The scan also revealed moderate to severe regurgitation at mitral, aortic and tricuspid valves. Rest of the relevant laboratory tests were normal. The NECT brain at admission showed loss of grey white differentiation in all of left occipital cortex and dense basilar artery sign. The cerebral CT angiogram showed occlusion of the tip of basilar artery with thrombus length of 3mm (Figure 1). In view of expected severe disability with tip of basilar syndrome,

iv thrombolysis was considered even in the presence of high NIHSS, presence of CT scan EIC changes and extended window period. Intravenous rtPA was readily instituted which subsequently resulted in a dramatic recovery with a robust improvement in her NIHSS to 3 within 6 hours. The follow-up NECT brain repeated 24 hours after thrombolysis showed hypo densities in left occipital cortex and left thalamus. CT scan repeated 10 days later showed complete resolution of hypo densities.

DISCUSSION

Intra-arterial thrombolysis is one of the most commonly used treatment for BA occlusion, however, the literature suggests that outcome is almost same in both intra-arterial and iv thrombolysis. A systemic review by Lindsberg et al has shown a significantly more achievable recanalization rate in intra-arterial compared to iv thrombolysis (65% vs 53%); the survival rates have been found to be almost similar though insignificant (50% vs 45%). It also showed that without recanalization, the likelihood of good outcome was 2% compared to 38% in patients with successful recanalization. A meta-analysis by Kumar et al has also demonstrated that recanalization of acute BA occlusion, whether by thrombolysis or endovascular therapy, lead not only to a significant reduction in mortality by two-fold but also a reduction in the risk of both death and dependency by 1.5-fold as well. Furthermore, using iv thrombolysis in BA occlusion, the success rate for recanalization has shown significant association with the length of the responsible thrombus, with recanalization rate of upto 80% in thrombi <10mm in size. Notably, this successful

recanalization rate was even better than seen in thrombi of middle cerebral artery. Even in patients with BA thrombi of >30 mm length, upto 30% success rate was substantially higher than minimal recanalization (<1%) of middle cerebral artery thrombi exceeding 8 mm . This is possibly the reason of successful recanalization in our patient as she only had a small thrombus length and at the tip of the BA occlusion and hence the successful recanalization . Another important element to consider is that the MRI diffusion-perfusion studies in posterior circulation ischemia have demonstrated that the mismatch exists well beyond 6 hours after the onset of symptoms. Therefore, the time window for thrombolysis for BA occlusion may presumably be longer than that for ischemic strokes involving other arterial territories . We presume that along with the short length of thrombus, this may have been a contributing factor in the good outcome of our patient with NIHSS of 31 to 3 within 6 hours of thrombolysis.

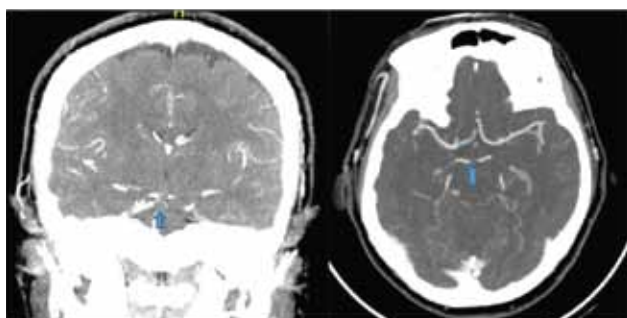


Figure 1: Cerebral CT angiogram, coronal and axial views, showing partial occlusion of the tip of basilar artery (shown by arrow).

Learning points

Acute onset brainstem signs in any patient should warrant the physician to consider a diagnosis of BA occlusion. Given the grave prognosis in untreated patients, ivrtPA can be a viable option in carefully

selected patients with acute BA stroke even with a severe NIHSS beyond the recommended 4.5 hours of thrombolysis window. The outcome of acute BA occlusion depends on the clinical state at presentation, the length and location of the occlusion, the degree of recanalization, and the time to treatment. Timely thrombolysis in a patient with acute cardio-embolic occlusion of the tip of BA carry a better chance of achieving a beneficial clinical outcome in terms of survival and functional independence.

REFERENCES

1. WJ Schonewille, CAC Wijman, P Michel, CM Rueckert, C Weimar, HP Mattle, et al. Treatment and outcomes of acute basilar artery occlusion in the Basilar Artery International Cooperation Study (BASICS): a prospective registry study. *Lancet Neurol* 2009; 8: 724–30.
2. EC Jauch, JL Saver, HP Adams Jr, et al. Guidelines for the early management of patients with acute ischemic stroke: a guideline for healthcare professionals from the American Heart Association/American Stroke Association. *Stroke* 2013; 44:870.
3. PJ Lindsberg, and HP Mattle. Therapy of Basilar Artery Occlusion. A systematic analysis comparing intra-arterial and intravenous thrombolysis. *Stroke*. 2006; 37:922-28.
4. G Kumar, RB Shahripour, and AV Alexandrov. Recanalization of acute basilar artery occlusion improves outcomes: a meta-analysis. *J NeuroIntervent Surg*. 2015;7:868-74.
5. D Strbian, T Sairanen, H Silvennoinen, O Salonen, and PJ Lindsberg. Intravenous Thrombolysis of Basilar Artery Occlusion Thrombus Length Versus Recanalization Success. *Stroke*. 2014;45: 1733-38.
6. JL Ostrem, JL Saver, JR Alger, S Starkman, MC Leary, G Duckwiler et al. Acute basilar artery occlusion: Diffusion-perfusion MRI characterization of tissue salvage in patients receiving intra-arterial stroke therapies. *Stroke* 2004; 35: e30

Conflict of interest: Author declares no conflict of interest.

Funding disclosure: Nil

Author's contribution:

Dr. Shaista A Siddiqi : Study concept and design, protocol writing, data collection, data analysis, manuscript writing, manuscript review

Dr. Syed Habibullah Kamran: data collection, data analysis, manuscript writing, manuscript review

Dr. Abubaker A Almadni: Study concept and design, manuscript writing, manuscript review