

ADEM, DIAGNOSTIC DILEMMA, A TERTIARY CARE HOSPITAL EXPERIENCE:

Rajesh Kumar¹, HazimBrohi², BushraRehan³, Syed Ijlal Ahmed⁴

¹ Senior Registrar Neurology Department LNH Karachi

² Associate Professor Neurology Department LNH Karachi

³ Assistant Professor Radiology Department LNH Karachi

⁴ Medical Student LNMC Karachi

Correspondence address: HazimBrohi (Associate Professor Neurology Department LNH Karachi); Email; hazimbrohi@yahoo.com
Date of submission: May 11, 2016 **Date of revision:** July 12, 2016 **Date of acceptance:** August 24, 2016

ABSTRACT

Acute disseminated encephalomyelitis (ADEM) is an uncommon inflammatory demyelinating disease of the central nervous system that usually occurs following a viral infection or vaccination, bacterial or parasitic infection, or even spontaneously. ADEM is a monophasic; poly symptomatic disorder but it may present with various combinations of motor, sensory, visual and cognitive symptoms. Some case reports of ADEM presented as psychiatric disorders primarily as confusion psychosis and at times dissociative disorder. At times, the diagnosis becomes a dilemma due to multifaceted picture. Due to confusion physician may go to extreme range of tests with no specific conclusion. Debates regarding exact diagnosis have always been there. Reports regarding ADEM are lacking from our country. The aim of our study is to look for the presenting features of the disease and the path to final diagnosis.

Keywords: ADEM, Demyelinating disease, diagnostic dilemma.

INTRODUCTION

Acute disseminated encephalomyelitis (ADEM) is an uncommon inflammatory demyelinating disease of the central nervous system that usually occurs following a viral infection but may appear following vaccination, bacterial or parasitic infection, or even spontaneously. 1The incidence rate is about 8 per 1,000,000 people per year.2It occurs in all ages; most reported cases are in children and adolescent, with the average age five to eight years.3,4, 5ADEM is a monophasic, polysymptomatic disorder. It may present with various combinations of motor, sensory, visual and cognitive symptoms. Some case reports of ADEM presented as psychiatric disorders primarily as confusion,6 psychosis7-8 and at times dissociative disorder.9 At times the diagnosis becomes a dilemma due to multifaceted picture so the diagnosis of ADEM should be considered to prevent unnecessary investigations. The aim of our study was to look for the presenting features, onset, course and radiological features of patients presented with ADEM. Reports regarding ADEM is lacking in our country. We could identify only two papers on ADEM from Pakistani journal during literature search on internet. The two papers were about children10-11.

METHODS

Our study was descriptive cross sectional study conducted at the department of neurology of Liaquat National Hospital, Karachi. We reviewed all adult patients who were finally labeled as ADEM from Jan 2014 to Dec 2014. Inclusion criteria were that the disease had to be monophasic, polysymptomatic neurological feature at onset and the imaging findings should correlate with demyelinating features. CSF should be negative for infections. The patients not fulfilling the above criteria were excluded from the study

RESULTS:

In our study out of 12 patients labeled ADEM, eight patients full filled the clinical and radiological features of ADEM. Details are described in Table No: 01

Table No: 1

Case No	Age/sex	Prodromal fever	Clinical	CSF Findings	Imaging Findings	Treatment	Outcome
(1)	18years/ Female	Headache for one week	Fits headache -1 week. weakness of all 4 limbs	Protein 67mg/dl WBCs 5	Cortical swelling with oedema in bilateral frontoparietal regions ,few of above lesions showed minimal enhancing on contrast	Three session of Plasma-phoresis and Steroids	Improved
(2)	19years/ Male	Fever 10 days	Paraplegia, urinary retention 5days, Unresponsiveness 1 day	Protein 93mg/dl, WBCs43, 90%lymphocytes	Multiple bilateral high signal areas in periventricular and subcortical white matter in frontoparietal, temporoccipital region and in thalamic region showing no contrast enhancement.	Steroids	Improved
(3)	20years/ Female	-----	Lower limb weakness for 3 months, Difficulty in speaking 8days and fits for 1day	Normal	Abnormal high signal in cortical and subcortical areas of bilateral frontotemporal and parietal region showing patchy enhancement.	ATT and Steroids	Improved
(4)	38years/ Male	Fever for 25 days	Fits for 10days and unresponsiveness for 2days	Protein 261mg/dl, WBCs 5	Abnormal signal in cortical and subcortical areas with cortical swelling bilateral in frontoparietal and temporal region with patchy contrast enhancement.	Steroids and Antiepileptics	Improved
(5)	30years/ Male	Fever for 3 days	Confusion followed by unconsciousness	Proteins 86mg/dl WBCs350 Mono90%	High signals in bilateral frontoparietal, temporal white matter, centrum semiovale. Also high signals in thalami, midbrain, pons and both cerebellar hemisphere.	Steroids	Expired
(6)	11years/ Female	Fever for 3days	Difficulty in walking 2days Drowsiness for 1day	WBC 75 (90% mono) Protein 66mg/dl	High signal seen in bilateral caudate and lentiformnuclei.also high signal with cortical swelling seen in bilateral frontoparietal and temporal region High signal intensity is seen in spinal cord extending from dorsal region to conusmedullaris. No contrast enhancement	Steroids (initially acyclovir, ceftriaxone and vancomycin for few days)	Improved
(7)	26years/ -----	-----	Unable to walk 5	WBC 20 Mono	Patchy areas of high signal intensity seen asymmetrically in bilateral	Steroids	Improved

(8)	22years/ Female	Fever and headache for 2days	Drowsin es, Lower limb weaknes s and urinary incontine nce for one week	Sugar 72mg/dl Protein 59mg/dl WBCs 138 Mono 90%	High signal seen in genu, body and splenium of corpus callosum, centrum semiovale and parietal periventricular region. High signal intensity extending from c2/c3 level to ConusMedullaris	Steroids	Expired
-----	--------------------	------------------------------------	---	--	---	----------	---------

DISCUSSION:

Two key elements, multifocal neurological presentation, and MRI imaging studies suggestive of demyelinating features are the key to identification of ADEM. As no verified clinical diagnostic criteria exist for ADEM¹² the diagnosis majorly relies on clinical suspicion. Typically acute disseminated encephalomyelitis (ADEM) is a condition that predominantly affects the white matter of the brain and spinal cord. It is an immune-mediated inflammatory demyelinating disease. It occurs in the wake of a clearly identifiable febrile prodromal illness or immunization. It manifests as monophasic, acute-onset encephalopathy of varied degrees with multifocal neurologic deficits. It has good response to steroids and is self-limiting.^{13, 14, 15} Other acute demyelinating syndromes (ADS), especially multiple sclerosis (MS) bears a strong resemblance to ADEM both pathologically and clinically. However ADEM is not easily distinguishable from alternative diagnoses on the basis of clinical features and neuroimaging findings. We now discuss the differences between the two diseases and review our cohort in the light of these differences. The most important and diagnostic tools is MRI studies. Classically the demyelinating lesion is identified by their margins, distribution in white matter and sparing of grey matter and basal ganglia. Certain studies have reported certain imaging differences. The lesions in MS have well defined margins, lesion sites are characteristic (periaqueductal, corpus callosum and periventricular) as compare to ADEM where lesions have poorly defined margins, tend to be in deep white matter with periventricular sparing. In spinal cord ADEM lesions tend to be large swollen and thoracic, while MS lesions tend to be smaller, discreet, and cervical. One most striking feature of ADEM is involvement of cortical and deep /basal ganglia grey matter¹⁶. In our study the key element that led to diagnosis of ADEM were the above described features. The scan showed involvement of both cortical and sub cortical regions, basal ganglia involvement. (for details see fig: 01-05) As both the disease (MS v:s ADEM) share a common pathological background i.e. demyelination, there are instances

where an illness initially diagnosed as ADEM is ultimately MS.¹⁷ We cannot comment that how many patients developed into MS as we do not have long term follow up. Other conditions that occur as part of disease spectrum of ADEM like bilateral optic neuritis, transverse myelitis, and neuromyelitisoptica may also occur as early manifestations of either MS.¹⁸ Debate has always existed regarding the clinical picture. Most important is the time of onset clinical signs. However the general understanding is that the sign and symptoms of MS are usually isolated (monosymptomatic) as compare to ADEM which tends to be polysymptomatic at the onset of presentation. This was true for all of our patients. The most striking presentation seen is that of rapid onset encephalopathy (45-75% in ADEM compare to MS which is 13-15%)¹⁶. In fact according to the diagnostic criteria used by International pediatric multiple sclerosis study group, encephalopathy is one of must diagnostic criteria.¹⁸ While comparing the literature and our cohort of patients, 5 of our patients were encephalopathic i.e. 62% of patients, which is within the literature range (45—75%). All of our patients did not had encephalopathy. Usually the disease occurs after a prodromal illness but it may be absent in quarter of patients¹⁹. Five of our patients had prodromal fever while the rest did have any prodromal illness. The clinical course is rapidly progressive and typically develops over hours to maximum deficits within days (mean of 4.5 days). A minority of cases show continued deterioration of function for a period as long as four weeks¹⁹. Controversy exists regarding the duration of monophasic period. Some may label the prolong phase as recurrent versus multiphasic ADEM. According to Mikaeloff it may extend up to 3.6 years²⁰ and according to the international pediatric MS study group ADEM is labeled as multiphasic if symptoms recur at least three month after the onset of initial ADEM attack and at least after one month of completing steroid therapy.^{21, 22} Disease course can be longer in ADEM as seen in literature particularly in adults compare to children²³. This was true in Two of our patients case no 03 and 07, who had longer course

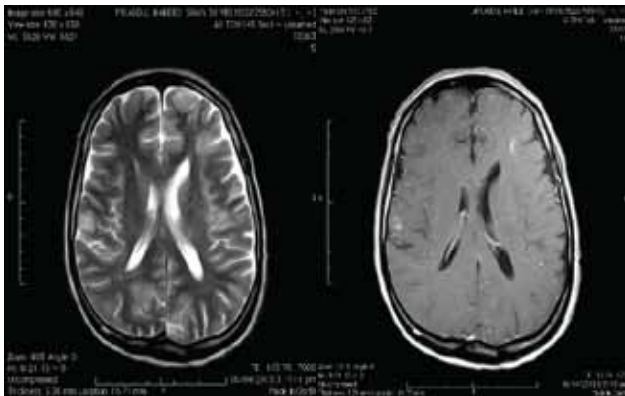


Fig:01. MRI brain of case No:04: Abnormal signal in cortical and subcortical areas with cortical swelling bilateral in frontoparietal and temporal region with patchy contrast enhancement.

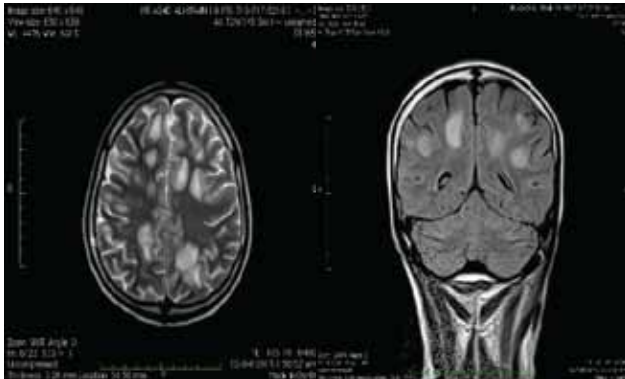


Fig:02 MRI brain of caseno: 02 Multiple bilateral high signal areas in periventricular and subcortical white matter in frontoparietal, temporoccipital region and in thalamic region showing no contrast enhancement

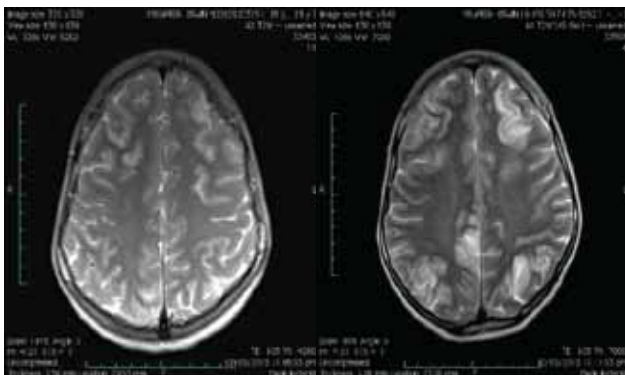


Fig:03 MRI Brain of case no:01 Cortical swelling with oedema in bilateral frontoparietal regions ,few of above lesions showed minimal enhancing on contrast

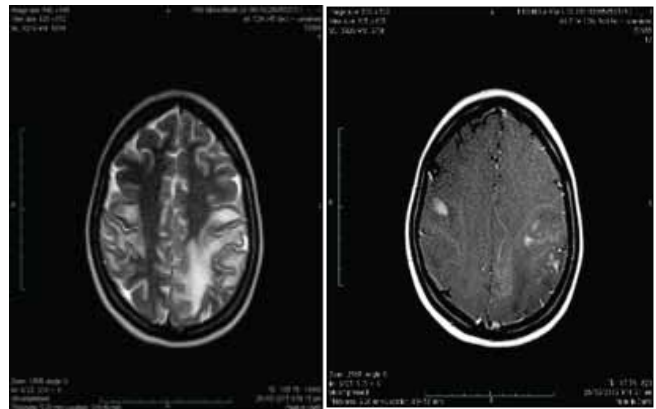


Fig:04 MRI brain of case no 03 Abnormal high signal in cortical and subcortical areas of bilateral frontotemporal and parietal region showing patchy enhancement.

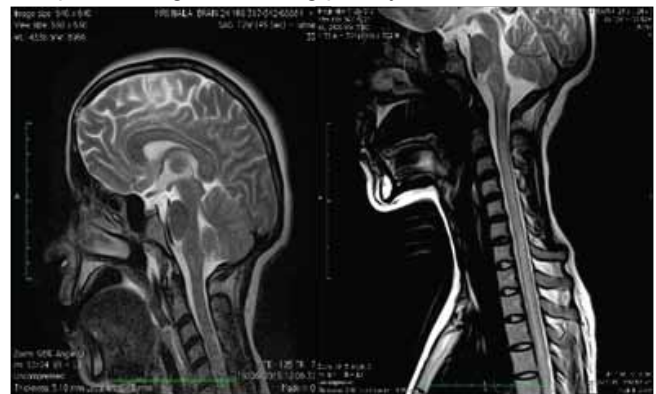

Fig:05 MRI brain and cervical spine of case no: 08 High signal seen in genu, body and splenium of corpus callosum, centrum semiovale and parietal periventricular region. High signal intensity extending from C2/C3 level to Conus Medullaris

of ongoing features of 3 months and 5 months respectively. Convulsive seizures occur around the onset of ADEM in as many as 35% of cases.¹⁹ Three of our patients had fits which is 37 % (3 out of 8) approximately. Both of these disorders can have optic neuritis but it is usually bilateral in ADEM whereas unilateral in MS.¹⁶ ADEM can be fulminant particularly in those having rapid severe onset of disease with extensive brain stem involvement and large lesion extending white matter and infratentorial¹¹ with mortality 20%²⁴. Two of our patients, Case No: 5 and 8 died due to fulminant disease. CSF findings of ADEM are not strongly infective. It may consist of lymphocytic pleocytosis and high proteins level. The CSF protein is higher in ADEM compared to MS while oligoclonal band is less commonly seen in ADEM compared to MS. In almost our entire patient had raised CSF protein only one patient has normal CSF DR. Oligoclonal band was not done in our study. This is the limitation in our study. Due to mixed nature of the disease it becomes at times very difficult to label the initial event. Thus the term clinically isolated syndrome of demyelinating disease (CIS) was coined. The literature shows that 30 to 70 percent of these events will progress to MS.²⁵

CONCLUSION:

In conclusion, diagnosis of ADEM rests on combination of history, clinical examination, MRI findings and CSF studies. It is only a high index of suspicion that will help to reach the diagnosis.

REFERENCES:

1. Prakash J et al, Acute disseminated encephalomyelitis presenting as dissociative disorder. *delhi psychiatry journal* vol. 13 No.1
2. Leake JA, Albani S, Kao AS, et al. Acute disseminated encephalomyelitis in childhood: epidemiologic, clinical and laboratory features. *pediatr. infect disease* 2004; 23 (8):756–64.
3. Hynson JL, Kornberg AJ, Coleman LT, Shield L, Harvey AS, Kean MJ. Clinical and neuroradiologic features of acute disseminated encephalomyelitis in children. *Neurology* 2001; 56 (10):1308–12.
4. Anlar B, Basaran C, Kose G, et al. Acute disseminated encephalomyelitis in children: outcome and prognosis. *Neuropediatrics* 2003; 34 (4):194–9.
5. Schwarz S, Mohr A, Knauth M, Wildemann B, Storch-Hagenlocher B. Acute disseminated encephalomyelitis: a follow-up study of 40 adult patients. *Neurology* 2001; 56 (10):1313–8
6. Tei H, Soma Y, Iwata M. Korsakoff's syndrome as the first clinical manifestation of acute disseminated encephalomyelitis. *BehavNeurol* 1995;(8):181–185
7. Moscovich DG, Singh MB, Eva FJ, et al. Acute disseminated encephalomyelitis presenting as an acute psychotic state. *Jnermnt dis* 1995; 183:116.
8. Nasr JT, Andriola MR, and Coyle PK. ADEM: literature review and case report of acute psychosis presentation. *Pediatrneurol* 2000; (22):8–18.
9. AbayE, BalciK, AtesI. Acute disseminated encephalomyelitis presenting as conversion disorder. *J neuropsychiatry clinneurosci* 2005; (17):259–260
10. Purkait R, Mukherji R, SinhamahapatraT, Bhadra R, Acute disseminated encephalomyelitis in a child following plasmodium vivax malaria. *journal of college of physician and surgeon of Pakistan* 2015, vol.25(7): 538–540
11. Alayafi HA, JahangiriFR, Almuntashri M, Fulminant Acute Disseminated Encephalomyelitis. *Pak J Med Res* vol. 53, No. 3, 2014
12. Young NP, WeinshenkerBG, and Lucchinetti CF, Acute disseminated encephalomyelitis: Current Understanding and Controversies *Semin neurol.* 2008 Feb;28(1):84–94
13. Rust RS. Multiple sclerosis, acute disseminated encephalomyelitis, and related conditions. *Seminpediatr Neurol.* 2000 Jun. 7(2):66–90
14. Tenenbaum S, Chitnis T, Ness J, Hahn JS. Acute disseminated encephalomyelitis. *Neurology.* 2007. 68(suppl 2):S23–S36
15. Dale RC. Acute disseminated encephalomyelitis. *SeminPediatr Infect Dis.* 2003 Apr. 14(2):90–5
16. Dale RC, BransonJA. Acute disseminated encephalomyelitis or multiple sclerosis can the initial presentation help in establishing a correct diagnosis. *Arch Dis Child* 2005;90: 636–639
17. Alper G. Acute disseminated encephalomyelitis. *J Child Neurol.* 2012 Nov. 27(11):1408–25.
18. Huppke P, Rostasy K, Karenfort M, Huppke B, Seidl R, Leiz S, et al. Acute disseminated encephalomyelitis followed by recurrent or monophasic optic neuritis in pediatric patients. *Mult. scler.* 2012 Nov 5
19. Kleiman M, Brunquell P. Acute disseminated encephalomyelitis: response to intravenous immunoglobulin. *J Child Neurol.* 1995 Nov. 10(6):481–3.
20. Mikaeloff Y, Caridade G, Husson B, Suissa S, Tardieu M. Acute disseminated encephalomyelitis cohort study: prognostic factors for relapse. *Eur J PaediatrNeurol* 2007;11(2):90–95

21. Krupp LB, Banwell B, Tenenbaum S for the International Pediatric MS Study Group. Consensus definitions proposed for pediatric multiple sclerosis and related disorders. *Neurology* 2007; 68(suppl 2):S7–S12.
22. Tenenbaum S, Chitnis T, Ness J, Hahn JS for the International pediatric MS study group. Acute disseminated encephalomyelitis. *Neurology* 2007;68(suppl 2):S23–S36
23. Ketelslegers IA et al, Disease course and outcome of acute disseminated encephalomyelitis is more severe in adults than in children. *Multscler.* 2011 Apr;17(4):441-8
24. Alexander M, Murthy JMK, Acute disseminated encephalomyelitis: Treatment guidelines. *Ann Indian Acad Neurol.* 2011 Jul; 14(Suppl1): S60–S64 Miller D et al. clinically isolated syndromes suggestive of multiple sclerosis; the lancet neurology 2005 may 6(4) 281–288.

Conflict of interest: Author declares no conflict of interest.

Funding disclosure: Nil

Author's contribution:

Rajesh Kumar: Study concept and design, protocol writing, data collection, data analysis, manuscript writing, manuscript review

HazimBrohi: Study concept and design, data collection, data analysis, manuscript writing, manuscript review

BushraRehan: Study concept and design, data analysis, manuscript writing, manuscript review

Syed Ijlal Ahmed: data analysis, manuscript writing, manuscript review