

DIAGNOSTIC DILEMMA IN NON-KETOTIC HYPERGLYCEMIC SEIZURES ON MR IMAGING

Javeria Sattar¹, Ateeq Ahmed Khan²

¹ Radiologist, Civil Hospital Karachi,

² Professor Radiology Dow University of Health Sciences

Correspondence to: Javeria Sattar, Radiologist, Civil Hospital Karachi, e-mail: jsattar99@yahoo.com

Date of submission: July 12, 2018 **Date of revision:** August 29, 2018 **Date of acceptance:** September 22, 2018

ABSTRACT

Acute metabolic encephalopathy is potentially a reversible condition and requires an early diagnosis and management to reduce morbidity and mortality, as in under diagnosed patients, permanent damage can result. Diabetic encephalopathy is an emerging complication of both type I and type II diabetes. Besides T1 hyperintensities in bilateral basal ganglia in diabetic encephalopathy patients, reported in most of the literature reviewed, patients with hyperglycemic seizures can present with subcortical hyperintensities, with predilection for occipital lobes. Here, we report a case of type II diabetic, 40 year-female patient who was referred for MR brain to our department, presented with acute symptoms of delirium, headache and fits, increased serum glucose levels at time of presentation. No T1 hyperintensities were identified in basal ganglia, instead the variable pattern of subcortical hyperintensities were identified with postcontrast patchy and gyriform enhancement. She was diagnosed with metabolic encephalopathy and referred back to referring clinician for adequate management. On follow up, patient improved clinically with insulin therapy. This report highlights the importance of early diagnosis of diabetic encephalopathy in patients with variable patterns on MR imaging, thus to avoid unnecessary medical treatment and prevent irreversible symptoms.

Keywords:

Diabetic encephalopathy, acute metabolic encephalopathy, non ketotic hyperglycemic seizures, MRI, hyperglycemia.

Introduction:

Encephalopathy is the state of diffuse cerebral dysfunction, secondary to systemic causes, metabolic derangements or drug toxicities. Diabetic encephalopathy has shown increased in the incidence as the incidence of type I diabetes has increased in recent years (1). Clinical presentation is variable, with the delirium being the most common presentation. Besides clinical evaluation and laboratory analysis of arterial blood gases and blood biochemistry, somatosensory evoked potential (SSEP), electroencephalography (EEG), and imaging methods like multislice spiral computed tomography (MSCT) and magnetic resonance imaging (MRI) are also required (2).

Case Report:

We report a known case of, 40 year female afebrile patient with uncontrolled type II diabetes on oral hypoglycemic drugs for ten years, presented with

headache for 4 days, delirium for 3 days and fits for 2 days. Fits initially begin in right upper limb which gradually progresses and involve whole body with uprolling of eyes and frothing from mouth (described as focal seizures with secondary generalization). Her neurological examination showed normal tone and bulk, reduce power in all four limbs and up going plantars bilaterally. Her blood pressure was within normal limits 120/80 mm Hg. Blood arterial gas analysis was normal with pH 7.5, pCO₂ 23.7, pO₂ 141, HCO₃, Sat O₂ and lactate 1.4. Her blood biochemistry showed increased glucose levels of 180 mg/dl and HbA1c of 12 mg%. Complete blood count and Electrolytes were within normal limits with normal EEG. Her urine analysis was negative for ketones. She received stat doses of I/V antibiotics in emergency, which were stopped when blood cultures came to be negative. She was referred for MR brain for further evaluation, which demonstrated T1 and T2 isointense signals with FLAIR hyperintensities in cortical and subcortical region of right posterior parieto-occipital lobes, showing linear as well as gyriform

ment on postcontrast images. These show restriction in Diffusion weighted images. Posterior reversible encephalopathy syndrome(PRES) and metabolic encephalopathy were included in differential diagnosis. PRES was excluded as patient's blood pressure was within normal limits and there was no clinical history of high blood pressures. Furthermore T2 isointense signals and post contrast gyriform enhancement do not favour PRES. Keeping in view the clinical history of patient, metabolic encephalopathy was considered the top diagnosis despite variable pattern of MR brain features. Patient was managed accordingly and followed during the course of the treatment which showed resolution of the signs and symptoms. Patient was discharged due to which repeat MR brain could not be performed.

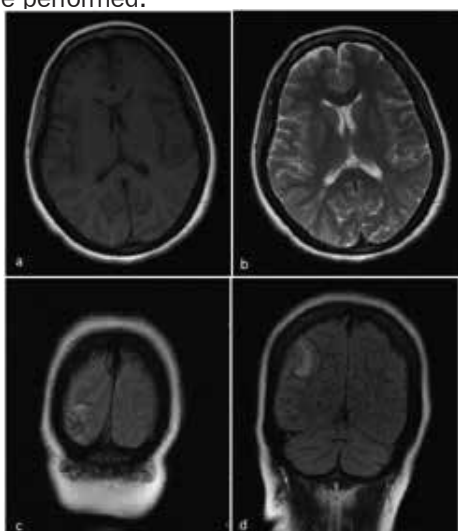


Figure 1 : a-T1WI, b-T2WI, c-d FLAIR images.

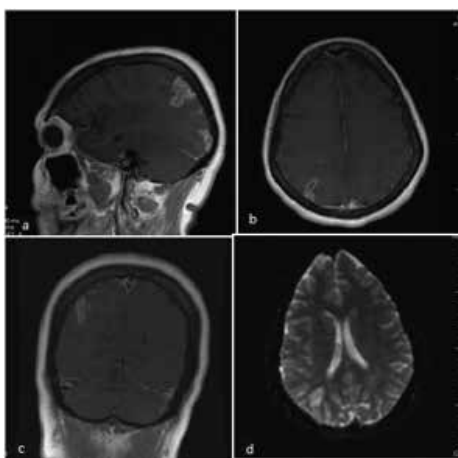


Figure 2: a-c post contrast images, d-DW image.

Discussion:

Kinner Wilson, in 1912, defined metabolic encephalopathy for the first time as the state of global cerebral dysfunction caused by systemic stress, which has variable manifestation from a very mild disorder to deep coma with decerebrate rigidity. It has been defined as diffuse cerebral dysfunction as well as a systemic disorder affecting hemispheres, reticular activating system and brainstem causing diffuse brain damage(2).

There are multiple causes for metabolic 'encephalopathy which include chronic organ diseases, electrolyte imbalances, hypo- or hyperglycemia, osmotic disorders, overdose of medications especially in intensive care units, multiple drug toxicity, alcohol or toxin abuse.

Neuroimaging including CT or MRI are important to exclude any organic or structural lesions of the brain. Patients with encephalopathy have usually normal CT and MRI brain. However, diffuse or focal edema, changes in the signal intensities in certain regions can provide clue to the diagnosis and underlying extracerebral pathology. Basal ganglia, thalamus, cerebral cortex, and hemispheric white matter are usually the target regions in metabolic encephalopathy.

To the best of the author's knowledge, literature review shows the characteristic appearance of nonketotic hyperglycemia (NKHG) is unilateral or asymmetrical bilateral lesions of the basal ganglia which are contralateral to the side of the patient's presenting symptoms. Similarly, on non-enhanced CT brain, putamen and / caudate nucleus show hyperdensities contralateral to the side of patient's symptoms (3).

Suárez-Vega VM et al. (4) reported rare case of Nonketotic hyperglycemic hemichorea-hemiballism (NHH) causing unilateral brain abnormalities, affecting basal ganglia and subtle hyperdensity in striatal region on CT scan of brain and T1 hyperintensity and T2 hypointensity in the basal ganglia contralateral to the movements on MR imaging.

Hyperglycemic seizures are more commonly seen in Non-Ketotic hyperglycemia (NKHG). Seizures can be focal with or without secondary generalization and occasionally occipital lobe seizures or epilepsia partialis continua (5). As seen in our patient, she suffered from focal seizures with secondary generalization.

tion secondary to the ictus can be seen. However, Subcortical areas of T2 hyperintensities are seen in subset of NKHG patients. The affected regions show T1 isointense, focal T2 hypointensity in the cortex but T2/FLAIR hyperintensities in underlying white matter with associated cortical swelling can also be seen. Gradient echo images also demonstrate subcortical hypointense signals. ADC values are transiently reduced, with focal cortical and leptomeningeal enhancement. In follow up scans, these can be either completely resolved or present as focal gliosis.

There is predilection for occipital lobes along with parietal, temporal and perirolandic cortex. These foci correlate with the ictal focus on EEG, which regresses with correction of hyperglycemia. Patients usually have elevated HbA1C levels.

Differentials for subcortical T2 hyperintensities include viral encephalitis, meningitis, hypoxic insult, Moyamoya disease. Differentials for leptomeningeal enhancement if present also include lymphoma, sarcoidosis and metastasis. Clinical history, hyperglycemic state and supportive EEG findings are the road map to accurate diagnosis.

Treatment usually targets for the correction of hyperglycemia, with which there is good response to the control of seizures. Thus antiepileptic drugs are not usually required except for few cases who may require short term management with phenobarbitol or valproic acid. In hyperglycemic states, phenytoin is avoided as it alters the glycemic control, thus aggravating the seizures.

Conclusion:

Diabetic encephalopathy is a potentially reversible acute metabolic encephalopathy requires an early accurate diagnosis, to plan appropriate management. Clinical background of poorly controlled diabetes with hyperglycemia, focal seizures with or without secondary generalization, in appropriate CT and MR findings are helpful to clinch the diagnosis. This report emphasizes the importance of metabolic causes of encephalopathy thus facilitating the prompt and appropriate management.

REFERENCES:

- 1 Sima A.F. Encephalopathies: the emerging diabetic complications. *Acta Diabetologica*; December 2010, Volume 47, Issue 4, pp 279–29
- 2 Berisavac VI, Jovanović DR et al. How to recognize and treat metabolic encephalopathy in Neurology intensive care unit. *NI FEATURE: THE QUEST – COMMENTARY*; 2017, Volume 65(1)123-128
- 3 Lai PH, Tien RD, Chang MH et al. Chorea-ballismus with nonketotic hyperglycemia in primary diabetes mellitus. *AJNR Am J Neuroradiol.* 1996 Jun-Jul;17(6):1057-64
- 4 Suárez-Vega VM et al. CT and MR Unilateral Brain Features Secondary to Nonketotic Hyperglycemia Presenting as Hemichorea-Hemiballism. *Case Reports in Radiology* Volume 2016 (2016).
- 5 Bathla G, Policeni B, and Agarwal A. Neuroimaging in Patients with Abnormal Blood Glucose Levels. *AJNR Am J Neuroradio*; May 2013 (10.3174)

Conflict of interest: Author declares no conflict of interest.

Funding disclosure: Nil

Author's contribution:

Javerya Sattar; concept, data collection, data analysis, manuscript writing, manuscript review

Ateeq Ahmed Khan; data collection, data analysis, manuscript writing, manuscript review