

SPORADIC HEMIPLEGIC MIGRAINE: A CHALLENGING DIAGNOSIS

Azra Zafar, Shahid Mustafa, Kaneez Aelia

Department of Neurology, Liaqat National Hospital, Karachi, Pakistan

Correspondence to: Dr. Zafar, Dept of Neurology, Liaqat National Hospital, Stadium Road, Karachi, Pakistan. Tel. (92-21) 450-2360. Email: thisisazra@yahoo.com

ABSTRACT

Migraine is a common, chronic, incapacitating neurovascular disorder characterized by attacks of severe headache, autonomic nervous system dysfunction and, in some patients, an aura involving neurological symptoms. Familial hemiplegic migraine (FHM) is characterized by the presence of hemiparesis and occasionally even severe coma during attacks. Sporadic hemiplegic migraine has also been described in the literature and has a clinical spectrum similar to FHM.

Migraine affects about 12% of the population in Western countries.¹ Familial hemiplegic migraine (FHM) is the only variety of migraine characterized by an autosomal dominant pattern of inheritance and transient hemiparesis followed by migraine headache.² Some sporadic cases of hemiplegic migraine with cerebellar signs have also been reported.³ Sporadic hemiplegic migraine (SHM) has clinical symptoms identical to FHM and distinct from migraine with aura.⁴

CASE REPORT

A 20-year-old right-handed gentleman presented with a 2-day history of left-sided weakness (evolving to maximum deficit over half an hour), followed by severe unilateral headache, vomiting and altered level of consciousness. Weakness was preceded by numbness of the left half of the body, and blurring of vision. There was no history of fever, neckache, sphincter dysfunction, abnormal movement, or head trauma. Over the last 8 years, the patient had experienced several similar episodes of less severe intensity, none lasting more than 4 hours. Frequency was variable ranging from 2 per month to once every 3-4 months. A brain CT scan and cerebrospinal fluid examination done in 1993 were normal. Subsequent brain CTs repeated CT at variable intervals were also normal.

Past medical, surgical and family history were unremarkable. He was unmarried, a non-smoker and did not consume alcohol. He had quit schooling after the 10th grade because of his illness. Medication use included

multiple analgesics, including intravenous injections for headache.

On examination at the time of admission, he was opening eyes on painful stimuli, localizing with the right hand, and had no verbal response. Power was 0/5 in the left half of the body with extensor plantar response on the left. He had a left facial nerve palsy of upper motor neuron type.

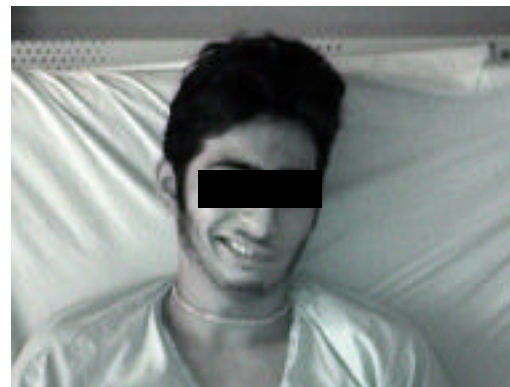

Figure 1: Left facial nerve palsy

He was moving the right side spontaneously, and there were no signs of meningeal irritation. Fundi were normal. Sensory, cerebellar, and gait examination were deferred. Routine blood tests including complete blood count, urea,

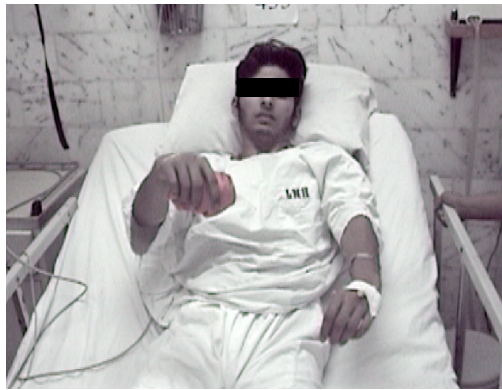

Figure 2: Left-sided hemiparesis

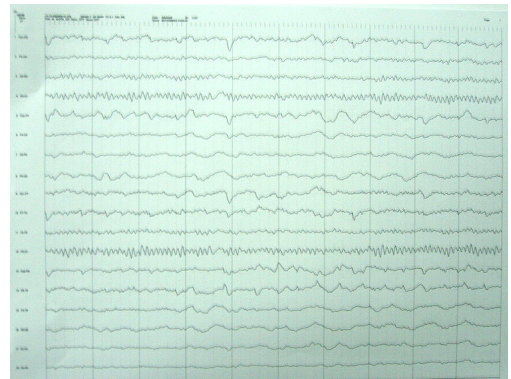

Figure 4: EEG showing right hemispheric dysfunction

creatinine, electrolytes, and random sugar were within normal limits. Anti-epileptic drug levels were in the sub-therapeutic range. Magnetic resonance imaging of the brain (including diffusion-weighted studies) was normal.

EEG showed severe right hemispheric dysfunction. The patient's family did not consent to CSF analysis. There was no significant clinical improvement after 3 days of

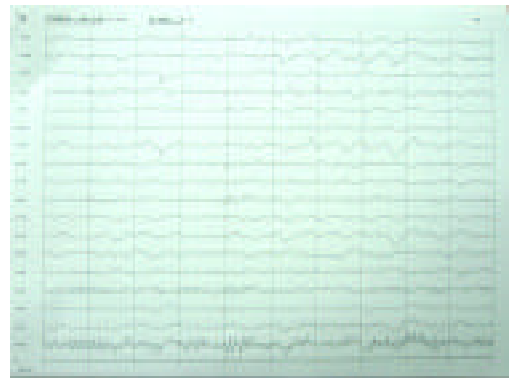


Figure 5: Repeat EEG showing some improvement

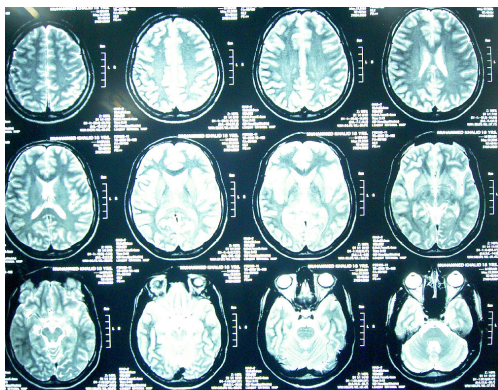


Figure 3: T2-weighted MRI of the brain (normal study)

hospitalization. An initial diagnosis of epilepsy (made in the past at another facility) was questioned. On the basis of a detailed history, exclusion of metabolic abnormalities, and normal neuroimaging, a diagnosis of sporadic hemiplegic migraine was tentatively made.

He was started on NSAIDs, flunarizine and valproic acid. Strength on the affected side gradually improved to 3/5,

he became fully conscious and oriented, and he was discharged on above medications. After 3 days, he was again hospitalized with severe headache, vomiting, imbalance, and drowsiness. He was given steroids for status migrainosus and intravenous verapamil (5 mg over 5 minutes), followed by oral verapamil (120 mg twice a day). Within 48 hours his power returned to normal and the headache subsided completely. Repeat EEG also showed improvement. A final diagnosis of SHM was reached.

DISCUSSION

Migraine is characterized by episodes of headache that are often throbbing, frequently unilateral, and may be severe. In migraine without aura (previously known as common migraine), attacks are usually associated with nausea, vomiting, and sensitivity to light, sound or movement. A combination of features is required for the

diagnosis, though not all features are present in every attack or every patient. Any severe and recurrent headache is most likely to be a form of migraine and to be responsive to anti-migrainous therapy. In 15% of patients, migraine attacks are usually preceded or accompanied by transient focal neurological symptoms; such patients have migraine with aura (previously known as classic migraine).⁵

Hemiplegic migraine was initially described in 1910 as a type of migraine consisting of recurrent headache associated with transient hemiparesis.⁶ Familial hemiplegic migraine (FHM) is a rare autosomal dominant form of migraine with aura in which some degree of hemiparesis is present during attacks. In FHM, the aura typically lasts longer than in migraine with aura and usually comprises visual, sensory, aphasic and motor symptoms.⁷ However, patients with similar clinical symptoms but without other affected family members have been reported, and the term sporadic hemiplegic migraine has been used.⁸ Based on the literature, two subforms of FHM families exist - pure FHM in 80% and FHM families with cerebellar symptoms in 20%.⁹ Mutations in the gene CACNA1A, which encodes a neuronal calcium channel, are present in 50% families with hemiplegic migraine including those with cerebellar signs.² Eight mutations in CACNA1A have been identified in 18 families affected by hemiplegic migraine and two patients with SHM.¹⁰ Genetic studies have revealed de novo mutations or incomplete penetrance of CACNA1A in patients with SHM.^{2,3} thereby suggesting that SHM may be part of the spectrum of FHM syndromes.

FHM is a disorder with an interesting and complex symptomatology. Motor aura symptoms are obligatory. Furthermore, 69% have concurrence of basilar migraine, with basilar-type symptoms during attacks. During episodes, 95% patients always experience a headache, 4% experience headache in some attacks, and 1 % never experience headache. Other associated symptoms include cerebellar ataxia associated with progressive cerebellar atrophy and epilepsy. FHM has a younger age of onset compared with migraine with aura.⁹

SHM has clinical symptoms identical to FHM. In SHM, presence of motor aura symptoms is essential. Other common aura symptoms are sensory (98%), visual (91%), and some form of aphasia (81%). Up to 72% of patients with SHM have concurrence of basilar migraine. Headache almost always occurs in close temporal relation to the aura, and SHM has an age of onset younger than 45 years.⁴ The most differential diagnoses of SHM typically includes epilepsy (post-ictal weakness following seizure, or Todd's phenomenon), transient ischemic attack or stroke,

metabolic abnormalities associated with focal deficits (hypercapnia, hypoglycemia, hyponatremia, hypocalcemia, hepatic failure and renal failure), meningitis or encephalitis, carotid dissection, anti-phospholipid antibody syndrome, SLE, and ornithine transcarbamylase deficiency.

Inherited disorders associated with migraine headache that may include hemiparesis include cerebral autosomal dominant arteriopathy with subcortical infarcts and leukoencephalopathy (CADASIL); mitochondrial myopathy, encephalopathy, lactic acidosis and stroke like episodes (MELAS); hereditary hemorrhagic telangiectasia (HHT); hereditary cerebral amyloid angiopathy; familial cerebral cavernous malformation; and benign familial infantile convulsions.⁴

Current therapeutic recommendations are based on isolated case reports and include propranolol,¹¹ phenytoin,¹² flunarizine,¹³ and verapamil.⁸ Successful responses of FHM to intravenous verapamil have been reported.¹⁴ Verapamil, administered either orally or intravenously, is also effective for SHM.¹⁵ Our patient had no further episodes after starting oral verapamil 240 mg daily, and was symptom-free at one-year follow up. SHM is a relatively rare disorder which should be considered in patients presenting with episodes of reversible neurological deficits with headaches; a therapeutic trial of calcium channel blocker (verapamil) may be administered.

REFERENCES

1. Stewart WF, Lipton RB, Celentano DD, Reed ML. Prevalence of migraine headache in the United States: relation to age, income, race, and other sociodemographic factors. *JAMA* 1992; **267**: 64-9
2. Ducros A, Denier C, Joutel A, Cecillon M, Lescoat C, Vahedi K, et al. The clinical spectrum of familial hemiplegic migraine associated with mutations in a neuronal calcium channel. *N Engl J Med* 2001; **345**: 17-24
3. Vahedi K, Denier C, Durcos A, Bousson V, Levy C, Chabriat H, et al. CACNA1A gene de novo mutation causing hemiplegic migraine, coma and cerebellar atrophy. *Neurology* 2000; **55**: 1040-2
4. Thomsen LL, Ostergaard E, Olesen J, Russell MB. Evidence for a separate type of migraine with aura: sporadic hemiplegic migraine. *Neurology* 2003; **60**: 595-601
5. Goadsby PJ, Lipton RB, Ferrari MD. Migraine - current understanding and treatment. *N Engl J Med* 2002; **346**: 257-67
6. Clark JM. On recurrent motor paralysis in migraine,

- with report of a family in which recurrent hemiplegia accompanied the attacks. *BMJ* 1910; 1534-1538
7. Benatar M, Ford CM. Familial hemiplegic migraine: more than just a headache. *Neurology* 2005; **64**: 592-3
 8. Razavi M, Razavi B, Fattal D, Afifi A, Adams HP. Hemiplegic migraine induced by exertion. *Arch Neurol* 2000; **57**: 1363-5
 9. Thomsen LL, Eriksen MK, Roemer SF, Andersen I, Olesen J, Russell MB. A population-based study of familial hemiplegic migraine suggests revised diagnostic criteria. *Brain* 2002; **125**: 1379-91
 10. Battistini S, Stenirri S, Piatti M, Gelfi C, Righetti G, Rocchi R, et al. A new CACNA1A gene mutation in acetazolamide responsive familial hemiplegic migraine and ataxia. *Neurology* 1999; **53**: 38-43
 11. Lai C, Ziegler DK, Lansky LL, Torres F. Hemiplegic migraine in childhood: diagnostic and therapeutic aspects. *J Pediatr* 1982; **101**: 696-699
 12. Ross RT. Hemiplegic migraine. *Can Med Assoc J* 1958; **78**: 10-16
 13. Tobita M, Hino M, Ichikawa N, Takase S, Ogawa A. A case of hemiplegic migraine treated with flunarizine. *Headache* 1987; **27**: 487-488
 14. Yu W, Horowitz SH. Familial hemiplegic migraine and its abortive therapy with intravenous verapamil. *Neurology* 2001; **57**: 1732-1733
 15. Yu W, Horowitz SH. Treatment of sporadic hemiplegic migraine with calcium channel blocker verapamil. *Neurology* 2003; **60**: 120-121